



THE AGA KHAN UNIVERSITY

eCommons@AKU

---

Section of Paediatric Surgery

Department of Surgery

---

1993

## Penile constrictive band injury

Zafar Nazir

*Aga Khan University*, [zafar.nazir@aku.edu](mailto:zafar.nazir@aku.edu)

Khalid Rasheed

*Aga Khan University*

Farhat Moazam

*Aga Khan University*

Follow this and additional works at: [https://ecommons.aku.edu/pakistan\\_fhs\\_mc\\_surg\\_paediatr](https://ecommons.aku.edu/pakistan_fhs_mc_surg_paediatr)



Part of the [Pediatrics Commons](#), and the [Surgery Commons](#)

---

### Recommended Citation

Nazir, Z., Rasheed, K., Moazam, F. (1993). Penile constrictive band injury. *Journal of the Pakistan Medical Association*, 43(7), 135-137.

Available at: [https://ecommons.aku.edu/pakistan\\_fhs\\_mc\\_surg\\_paediatr/19](https://ecommons.aku.edu/pakistan_fhs_mc_surg_paediatr/19)

# Penile Constrictive Band Injury

Pages with reference to book, From 137 To 139

Zafar Nazir, Khalid Rasheed, Farhat Moazam ( Department of Surgery, The Aga Khan University Hospital, Karachi. )

## Abstract

Penile strangulation caused by a thread or human hair is an uncommon cause of urethral injury described in paediatric practice. Five children presented with this entity to the Aga Khan University Hospital, Karachi between August, 1991 and August, 1992. Three children had uneventful recoveries after removal of the constricting agent. Two patients developed urethrocutaneous fistulae and partial amputation of the penis because of late presentation. Early recognition and removal of the constricting agent is necessary to prevent serious complications (JPMA 43: 135, 1993).

## Introduction

Penile tourniquet or constrictive band injury caused by an encircling object has been described periodically in all ages<sup>1,2</sup>. The constricting bands are placed on the penis for a variety of reasons and the objects used have been diverse<sup>3,4</sup>. In children rubber bands, threads and human hair have been reportedly used to prevent nocturnal enuresis or incontinence and sometimes as childhood experimentation<sup>5-7</sup>. Severe damage to the erectile tissue and urethra can result, requiring major reconstructive procedures. The purpose of this report is to call attention to this injury in young children and to stress the importance of early recognition and management.

## Patients and Methods

Between August, 1991 and August, 1992 five children presented to the paediatric surgery service at The Aga Khan University Hospital, Karachi, with penile constrictive band injury. The medical records were reviewed retrospectively for age at presentation, circumcision, history of nocturnal enuresis, nature of constricting agent, duration before diagnosis, presenting symptoms and signs, treatment and the outcome. The injuries were graded as described by Bashir and El-Barbary<sup>8</sup> (Table I).

**Table I. Grading of Penile constrictive band injury.**

---

Grade 0 - Constriction of skin without urethral injury.

Grade 1. Partial division of corpus spongiosum with urethrocutaneous fistula.

Grade 2. Complete division of corpus spongiosum and constriction of corpus cavernosum.

Grade 3. Gangrene, necrosis and amputation of the glans

---

(Bashir, A.Y., El-Barbary, M. J.Roy.Coll.Surg., 1980;25:47).

## Illustrative Case Report

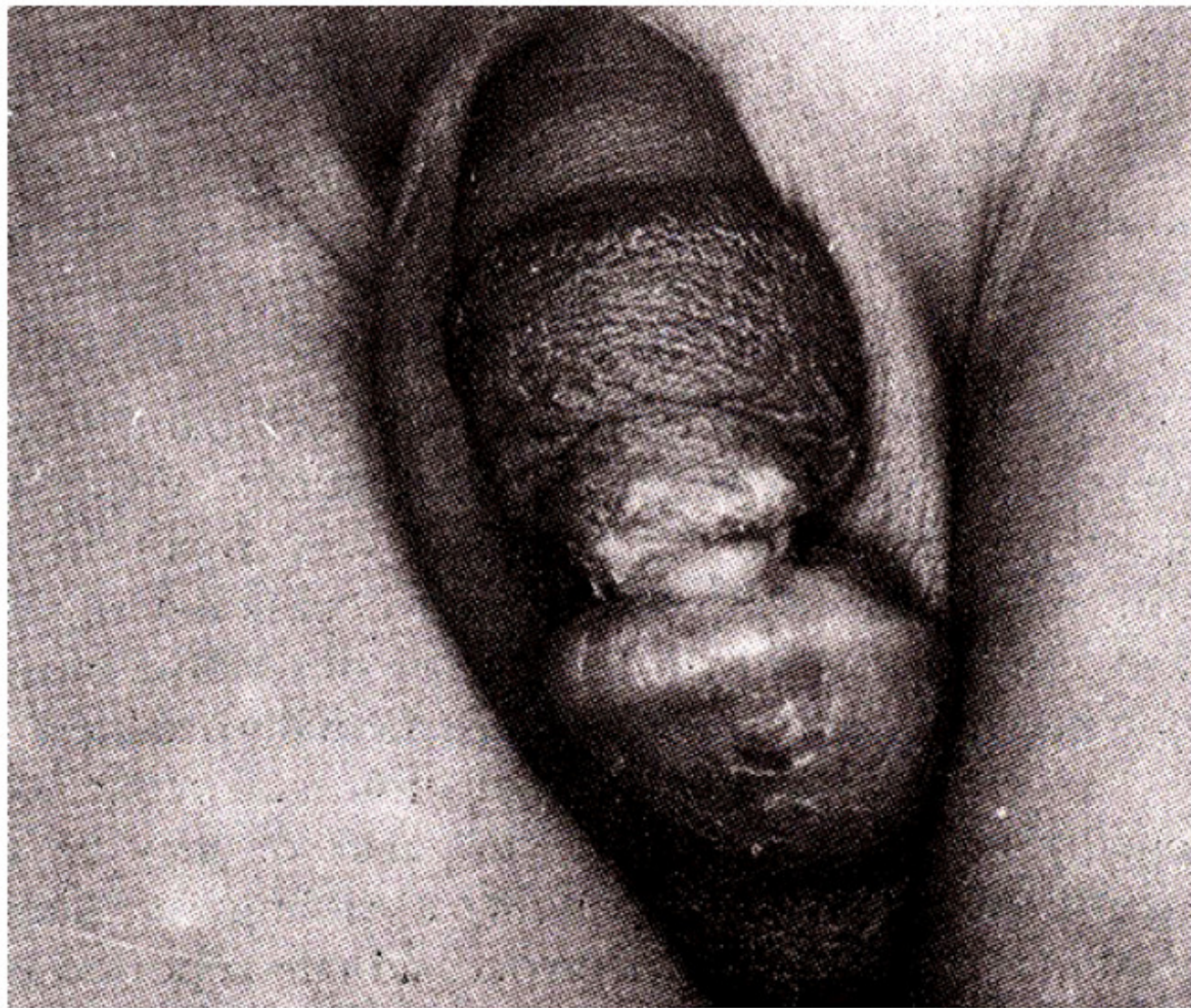
S.I.U., a seven year old circumcised boy (patient 4 in Table II)



**Table II. Features of Penile constrictive band injury.**

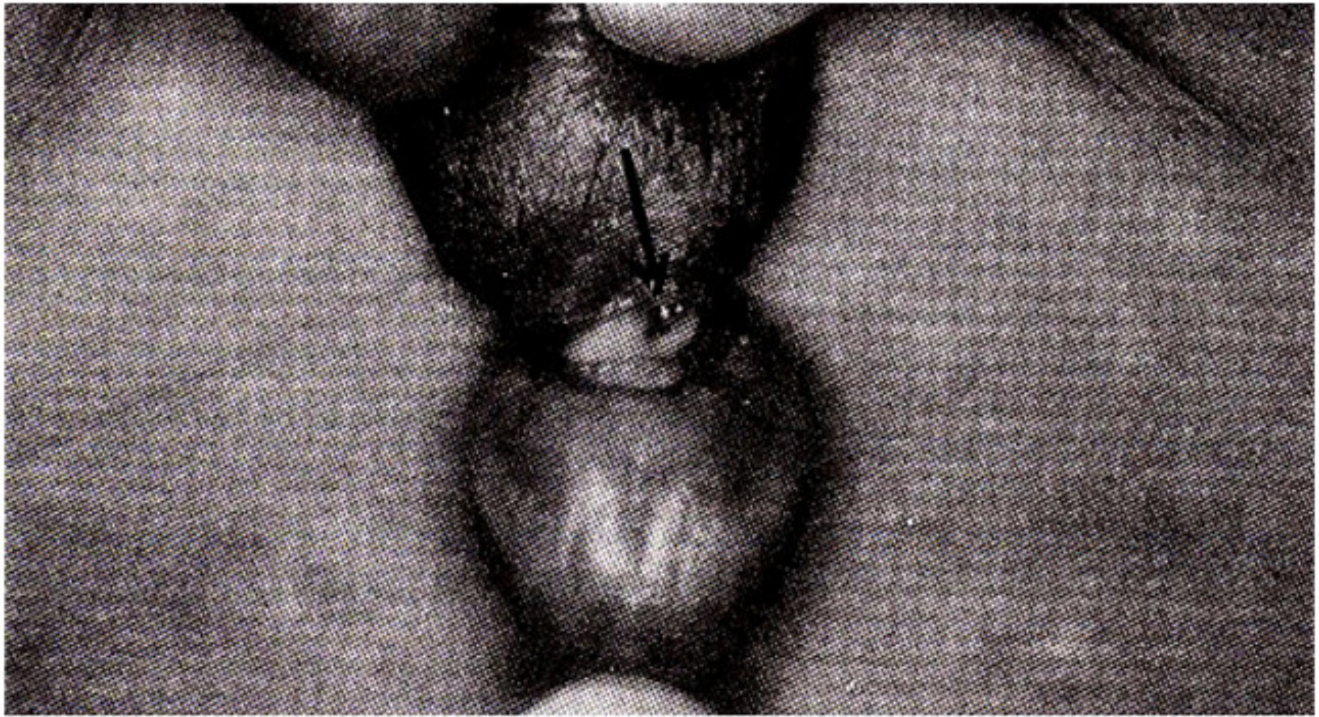
No.	Age at presentation	Circumcised	History of enuresis	Constricting agent	Delay in diagnosis	Marked erosion of coronal sulcus	Glans edema	Retention of urine	Urethral fistula	Injury grade
1.	6 months	Yes	-	Human hair	2 weeks	Yes	Yes	No	No	0
2.	4 years	Yes	No	Cotton thread	4 weeks	Yes	Yes	No	Yes	1
3.	6 years	Yes	No	Human hair	2 weeks	Yes	Yes	Yes	No	0
4.	7 years	Yes	Yes	Polyester thread	3 weeks	Yes	Yes	No	Yes	2
5.	9 years	Yes	Yes	Polyester thread	2 weeks	Yes	Yes	Yes	No	0

with a history of nocturnal enuresis, tied a thread around his penis to control bed wetting and avoid paternal punishment. He concealed the swelling of the glans until one week later, when he was seen by a local physician for progressive penile swelling and circumferential inflammation at the coronal sulcus. The child was placed on systemic antibiotics with no response. In the third week following the episode, the physician discovered an encircling thread, buried in the coronal sulcus. Following its removal, the patient developed an urethrocutaneous fistula and was referred to The Aga Khan University Hospital. Examination under anaesthesia revealed complete division of the corpus spongiosum, leading to a urethral fistula and partial amputation of the corpus cavernosum (Grade 2 injury). The glans was markedly swollen (Figure 1a and 1b).



**Figure 1a. Marked edema of glans and partial amputation of corpora cavernosum.**





**Figure 1b. Ventral surface of penis showing urethral fistula.**

After wound debridement, the glans was sutured to the corpora cavernosum. The youngster is awaiting elective repair of the fistula.

## **Results**

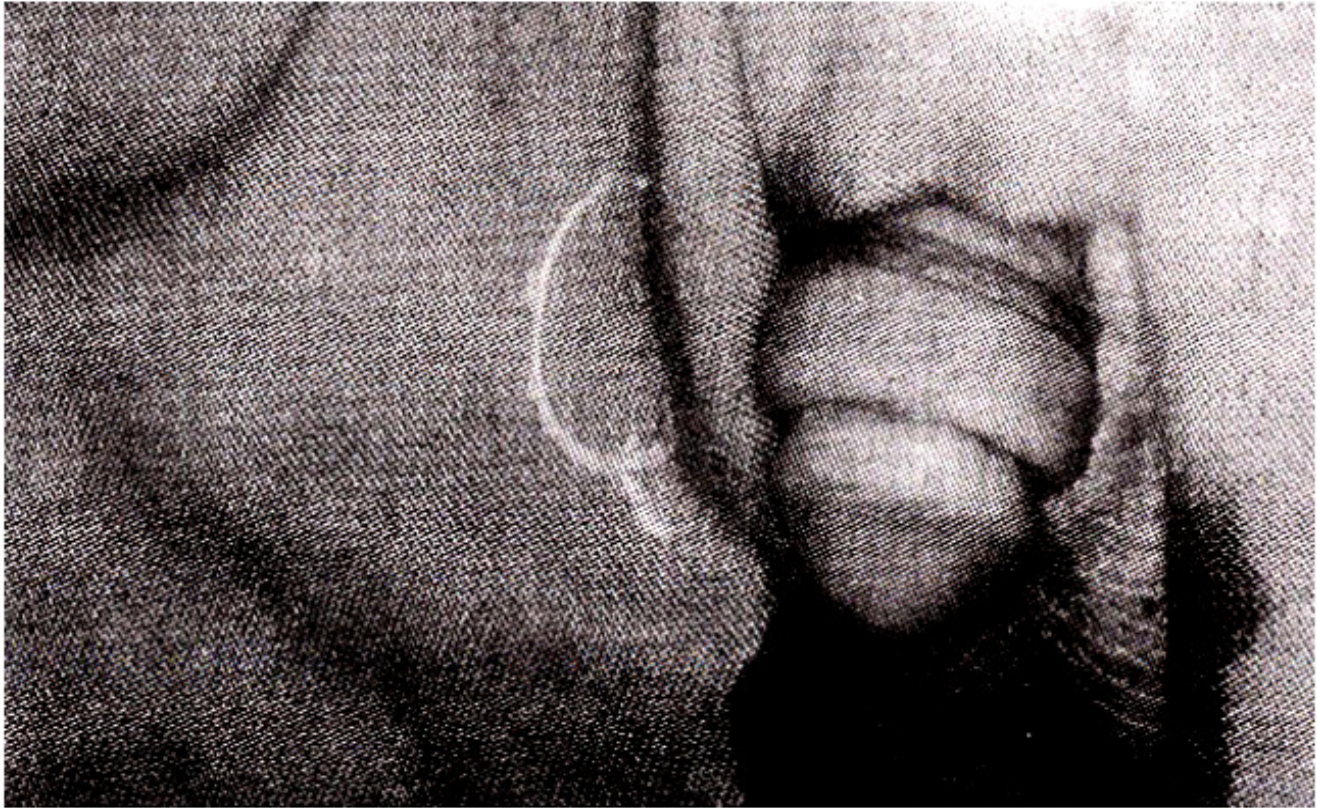
The salient features of the patients are summarized in Table II. The average age of the patients was 5.2 years, with a range of 6 months to 9 years. All children had been circumcised at birth. Two patients admitted to tying polyester thread around the penis to control nocturnal enuresis. In one patient the cotton thread was tied by an elder sibling. The mean time interval between occurrence of the event and recognition of the constricting agent was 2.6 weeks (range 2 to 4 weeks). The physical and mental development in all children was normal for age.

## **Discussion**

If unrecognized, penile constrictive band injury can result in serious sequelae. The first case of such an injury secondary to human hair was reported by Morgenstern in 1888g. Since then occasional reports have appeared in medical literature describing mostly adult patients, some of whom were mentally disabled<sup>1-3</sup>. In children, penile strangulation may occur accidentally by the hair of the caretaker or may be an intentional act by the patient, a sibling, or family members. This injury has been occasionally reported as a form of child abuse<sup>5</sup>. As in previous reports, all the patients in our series were circumcised. Circumcision makes the coronal sulcus more accessible to the constricting agent and may be a reason why this injury has never been reported in uncircumcised children<sup>6</sup>. The extent of the damage is related to the duration of constriction and the nature of the constricting agent. The corpus spongiosum and the penile urethra are covered by a thin layer of fibrous tissue, and therefore, are more susceptible to injury than the corpus cavernosum which is enveloped by the dense tunica albuginea<sup>2,6</sup>. Progressive compression of the penile vessels is responsible for distal oedema and gangrene. The



neural bundle may be injured effecting the sensation of the glans. If the constricting agent cuts through the ventral aspect of the penis, the urethra is transected resulting in a urethrocutaneous fistula. Human hair and thread can be easily over-looked once the swelling of the glans ensues, resulting in extensive injury. Two patients in the present series had a delay in diagnosis of 3 and 4 weeks and developed urethral fistulae. Unexplained edema of the glans with a marked erosion of the coronal sulcus and surrounding inflammation in a young child should be viewed with a high index of suspicion. An underlying circular constricting agent should be included in the differential diagnosis of penile swelling beside local infection (balanitis) paraphimosis, trauma, contact dermatitis and insect bites. Confirmation of the diagnosis may require a thorough examination under general anaesthesia. If diagnosed early, removal of the constricting agent and local care of the wound is all that is necessary (Figure 2).



**Figure 2. Constricting cotton thread removed from patient 2 (Table II). Note pronounced coronal sulcus.**

Reconstruction of the transected urethra should be delayed until the inflammation has resolved and the tissues have healed. Long term follow-up may be necessary to detect urethral strictures and possible sexual dysfunctions.

## References

1. Boat, AL, Kumar, A., Mathur, S.C. et al Penile strangulation. *Br.J. Urol.*, 1991;68:618-21.
2. Stoller, M.L., Lue, T.F. and McAninch, 1W. Constricting penile band injury: anatomical and reconstructive considerations. *UroL*, 1987;137:740-42.
3. Sinha, B.B. Penile incarceration by a metallic object. *Br.). Surg*, 1988;75:33.
4. Fiumara, NJ. Annular constriction of penis; the tourniquet syndrome. *JAMA.*, 1978;240:2353-54.
5. Snyder, N.M. and Caldamone, A.A. Genitourinary injuries, In. K.J. Welch, J.G. Rondoiph and M.M. Ravitch et al eds. *Pediatric surgery*, Chicago, Year Book Medical Publisher Inc., 1986, pp. 174-85.

6. Sheinfeld, J., Cot, L.R., Erturk, B. et al Penile tourniquet injury due to coil of hair. 1 UroL, 1985;133:1042-43.
7. Alpert, J.J., Filler, Rand Glaser, H.H. Strangulation of an appendage by hairwrapping, N. Engl. J. Med., 1965;273:866-67.
8. Bashir, A.Y. and El-Barbary, M. Hair coil strangulation of the penis. 3. Roy. Coil. Surg. Edin., 1980;25:47-51.
9. Morgenstern, 3. Retention of urine and edema of penis from constriction by hair. Pediatrics, 1888;5:248.