



THE AGA KHAN UNIVERSITY

eCommons@AKU

Department of Radiology

Medical College, Pakistan

February 2012

Portal biliopathy

Muhammad Shahbaz Alam
Aga Khan University

Qazi Saad Bin Khalid
Aga Khan University

Muhammad Zeeshan
Aga Khan University

Zishan Haider
Aga Khan University

Follow this and additional works at: http://ecommons.aku.edu/pakistan_fhs_mc_radiol



Part of the [Radiology Commons](#)

Recommended Citation

Alam, M., Bin Khalid, Q., Zeeshan, M., Haider, Z. (2012). Portal biliopathy. *Journal of the Pakistan Medical Association*, 62(2), 177-80.
Available at: http://ecommons.aku.edu/pakistan_fhs_mc_radiol/18

Portal biliopathy

Muhammad Shahbaz Alam, Qazi Saad Bin Khalid, Muhammad Zeeshan, Zishan Haider
Department of Radiology, Aga Khan University Hospital, Karachi, Pakistan.

Abstract

Portal biliopathy (PB) is a rare disorder, which mostly presents as sub-clinically. It occurs most commonly due to idiopathic extrahepatic portal vein obstruction. We present three cases having features of portal biliopathy secondary to portal hypertension. Our first case did not have a prior history of chronic liver disease while next two patients had previous history of chronic liver disease resulting in portal hypertension. Cavernous transformation of the portal vein due to extrahepatic portal vein obstruction is not infrequent but biliary obstruction in association with this disorder is distinctly uncommon. Proper case management is very important as prolonged biliary duct obstruction can lead to the development of ascending cholangitis or later on secondary biliary cirrhosis.

Keywords: Portal biliopathy, Portal vein obstruction, Portal hypertension.

Introduction

Portal biliopathy can be defined as biliary ductal and

gall bladder wall abnormalities secondary to portal hypertension, more commonly due to portal vein thrombosis.^{1,2} In 30% cases of portal biliopathy, extrahepatic portal hypertension is the predisposing factor, in as many as half of the patients there is no predisposing cause.³ The changes in biliary and portal channels include dilated intra and extrahepatic biliary ducts, varices formation around porta hepatis due to portal hypertension caused by the portal vein obstruction. This can rarely result in cholelithiasis and choledocholithiasis formation secondary to biliary stasis.^{3,4}

The major presenting features of portal biliopathy are variceal bleeding, ascites, splenomegaly and encephalopathy. Jaundice is rarely seen in portal hypertension⁴ except in patients with history of underlying chronic liver disease. We present three cases having features of portal biliopathy secondary to portal hypertension. Our first case did not have prior history of chronic liver disease while the next two patients had a previous history of chronic liver disease resulting in portal hypertension.

Case-1:

A 30-year-old young gentleman presented with history of fever with chills and dry cough for the past five days. He also had epigastric burning sensation for which he took Ranitidine and oral antacids. Patient also contacted chest tuberculosis four years back for which he was treated for one year. The physical examination showed that his vitals were normal. He had jaundice however, and no anaemia. Systemic examination was also normal with soft, non-tender abdomen and no visceromegaly. Laboratory examinations included serum bilirubin of 4.4 mg/dl and raised alkaline phosphatase of 478 IU/L. Haemoglobin was 13.2 mg/dl and WBC of 5.7×10^9 with 66% neutrophils. Viral profiles including Hepatitis A, B, C, D and E were negative.

Ultrasound and CT scan were performed at the Department of Radiology, The Aga Khan University Hospital as diagnostic procedures. Extensive intrahepatic biliary dilatation was noted with numerous intrahepatic biliary duct calculi and sludge on ultrasound examination (Figure-1-a). However Common bile duct (CBD) could not be evaluated because of extensive peripancreatic and porta-hepatis varices (Figure-1-b). Varices were also seen at splenic hilum. No abdominal lymphadenopathy or ascites were noted.

Further workup with CT scan redemonstrated intrahepatic biliary dilatation with non-visualization of extra hepatic part of CBD. Low-density material was observed in intrahepatic ducts suggestive of sludge/calculi. Portal vein was not visualized separately. Marked collateral vessels were seen in the region of gastro hepatic ligaments extending into the porta-hepatis down to the level of renal hilum. However; there were no focal lesions or changes suggestive of chronic liver disease. Percutaneous transhepatic decompression of biliary system was performed to relieve the patients signs and symptoms due to biliary obstruction. Therefore, based on

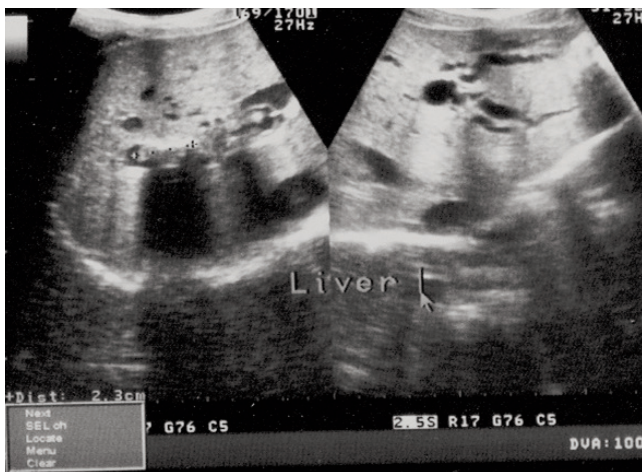


Figure-1 (a): Ultrasound liver showing intrahepatic biliary dilatation with multiple calculi.

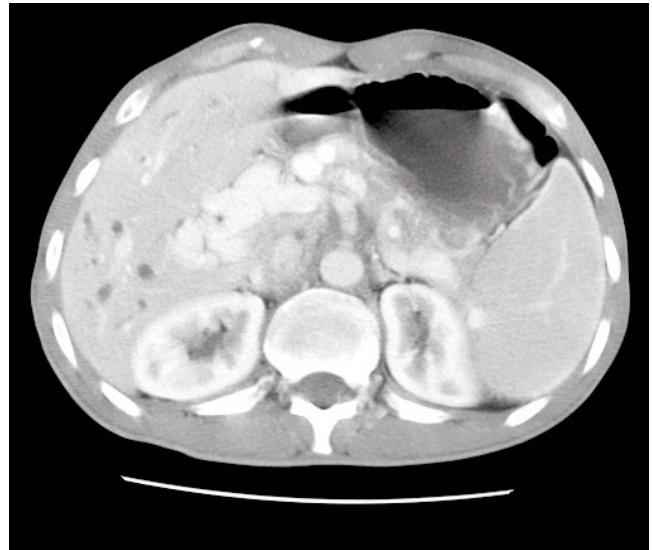


Figure-1 (b): CT Scan: Extensive peripancreatic and porta hepatis varices with intrahepatic biliary duct dilatation.

clinical and imaging findings, diagnosis of portal biliopathy was made by the radiologist. Further follow-up of the patient was not available as the patient was lost to follow-up.

Case-2:

A 19-year-old female, known case of hepatitis C, Protein C and S deficiency, presented with bloody vomiting and black colour stools for 1 day in Emergency Department. Vitals showed tachycardia with hypotension. Physical examination was unremarkable. Her liver function test was performed which was within normal limits. Direct Bilirubin was 0.5 mg/dl while alkaline phosphatase was 98 IU/L.

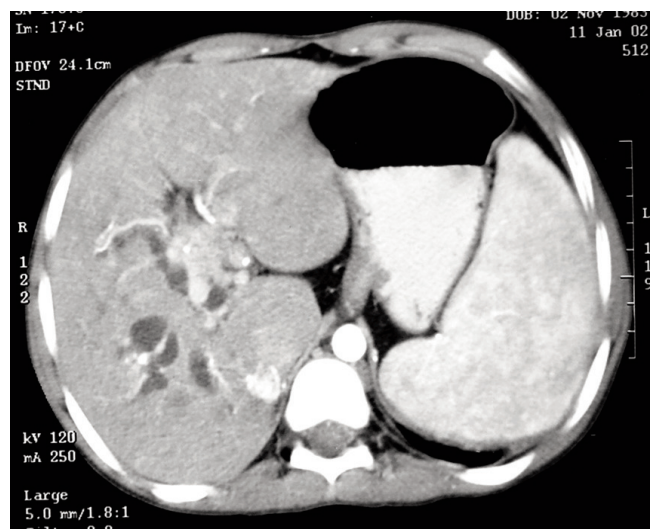


Figure-2 (a): Cavernous transformation of portal vein with multiple varices at porta hepatis with intrahepatic biliary duct dilatation.

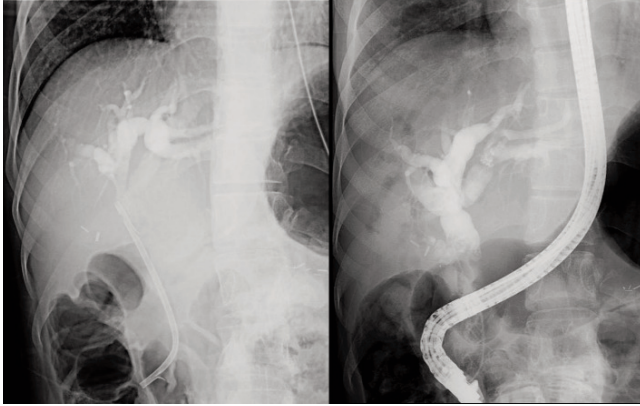


Figure-2 (b): ERCP showing s narrowing of CBD with intrahepatic biliary dilatation and stent placement.

Follow-up alkaline phosphatase values were 144 and 359 IU/L respectively.

After initial assessment and management, endoscopy was done and band ligation was performed. Subsequently, ultrasound and CT abdomen were carried out which showed moderate intrahepatic biliary dilatation, gallstones, thrombosed portal and superior mesenteric veins, aneurysmal dilatation of the portal vein along with multiple dilated collateral seen at the porta hepatis, which were compressing the CBD at its mid level (Figure-2). Distal CBD at the head of the pancreas showed normal caliber, thus based on radiological features, diagnosis of Portal Biliopathy was made.

Furthermore, patient was followed in outpatient clinics. Multiple admissions were made because of recurrent cholangitis. Elective cholecystectomy followed by biliary stent placement was done via ERCP and patient now showed improvement in her symptoms.

Case-3:

This is another case of a 30 year old young male who was a known case of chronic liver disease and presented with history of abdominal pain in the emergency room. His initial lab investigations showed raised total bilirubin of 1.4 and direct bilirubin of 0.2. Alkaline phosphatase was in normal range of 122 IU/L. Hepatitis B surface antigen and HCV Antibody were negative. He also had a history of upper gastrointestinal bleed six months back. Endoscopy was performed at that time which showed Grade IV varices for which band ligation was done outside of our hospital. Ultrasound at that time showed features of chronic liver disease with cavernous transformation.

CT scan was ordered as a workup procedure which showed cavernous transformation of portal vein with multiple collaterals at porta hepatis and peripancreatic region resulting in mild intrahepatic biliary dilatation secondary to

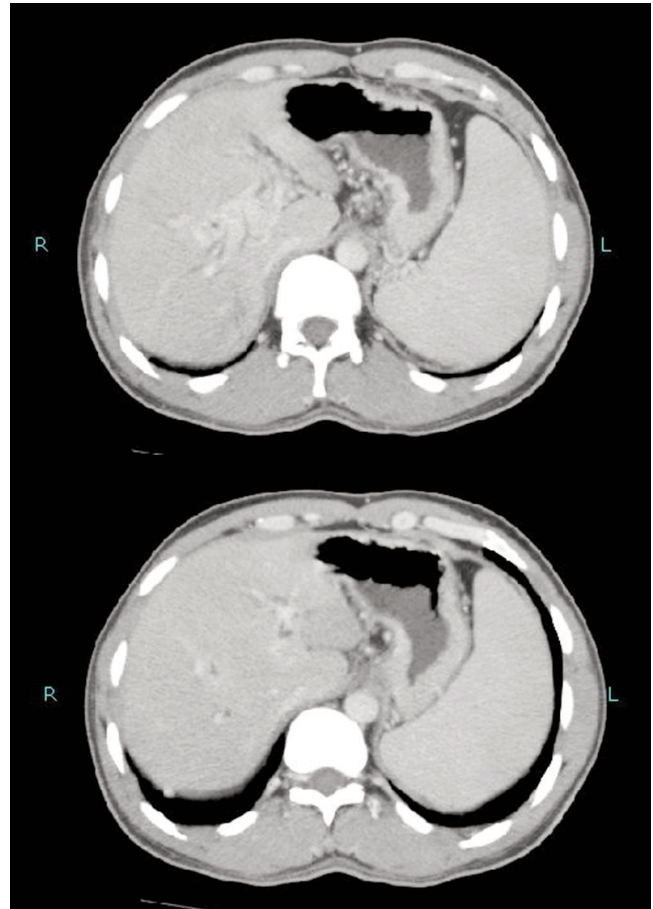


Figure-3 (a,b): CT Scan: Multiple collaterals at porta hepatis with intrahepatic biliary duct dilatation.

compression of distal common bile duct by these varices (Figure-3-a,b). Features of chronic liver disease with splenomegaly were also noted. Therefore, on the basis of imaging, diagnosis of portal biliopathy was made.

Patient was conservatively managed at that time. Further follow-up of the patient after three month in outpatient clinic was done. Patient was doing well with no complain of abdominal pain or haematemesis.

Discussion

Portal biliopathy is not the only cause of portal hypertension, there can be other intrahepatic and extrahepatic causes. While the extrahepatic causes include congenital portal vein obstruction, umbilical sepsis, trauma, hyper coagulation state like Budd-Chiari Syndrome and malignant occlusion, intrahepatic causes can be cirrhosis and primary biliary cirrhosis.^{3,4}

The extrahepatic portal vein thrombosis causes formation of collateral channels mainly around porta hepatis,

gastro hepatic ligament and splenic vein.⁵ These collaterals sometimes become large enough to cause compression and obstruction of common bile duct extrahepatically or intrahepatically.⁶ This occurs because bile duct is a low pressure system compared with portal channels.

In the first case, the patient had a very short history of portal hypertension and radiological findings clearly demonstrated by extrahepatic bile duct obstruction that resulted in intrahepatic biliary duct dilatation, sludge and calculi formation. Portal vein was totally thrombosed and CBD could not be found in its normal course as portal vein collaterals compressed it. Other two cases have prior history of chronic liver disease with secondary features of portal hypertension.

These are unusual presentations for cases of portal hypertension. Only few cases reported earlier had such grave presentation. For instance, Sumanthi et al⁴ presented a case of portal hypertension with obstructive jaundice secondary to portal biliopathy. Similarly, Chawla et al³ reported a case of portal biliopathy with obstructive jaundice and haemetemesis. The radiological findings in the current cases also suggested extensive periportal and peripancreatic varices, which caused almost complete compression of CBD.⁶ Moreover, intrahepatic dilatation with calculi formation was also seen in first case. So the radiological appearances of these cases are very typical of portal biliopathy as one does not often see the extrahepatic compression of CBD by collateral channels. This feature is not really seen in other causes of portal hypertension.

Proper case management is very important as prolonged biliary duct obstruction can lead to the development of ascending cholangitis or later on secondary biliary cirrhosis.^{2,7} Management of portal biliopathy depends upon clinical manifestations. Asymptomatic patients generally do not require treatment. CBD calculi can be removed by endoscopic retrograde

cholangiopancreatography (ERCP) and if there is stricture or narrowing in the duct, stent can be placed. Stones causing obstruction can be removed by endoscopic sphincterotomy. Care should be taken, as there are large venous collaterals around ampullary region, which can bleed profusely. In patients with symptomatic biliary obstruction not amenable to endoscopic therapy, a Porto systemic shunt is indicated to decompress the portal system.^{4,8} If changes of portal biliopathy do not regress even then, hepaticojunostomy can be performed to alleviate biliary obstruction.

Conclusion

Cavernous transformation of the portal vein due to extrahepatic portal vein obstruction is not infrequent but biliary obstruction in association with this disorder is distinctly uncommon. Proper case management is very important as prolonged biliary duct obstruction can lead to the development of ascending cholangitis or later on secondary biliary cirrhosis.

References

1. Aziz F, Ashraf P, Sophie Z. Non-Cirrhotic portal hypertension in young adult. *J Coll Physicians Surg Pak* 2000; 10: 306-7.
2. Chandra R, Kapoor D, Tharakan A, Chaudhary A, Sarin SK. Portal biliopathy: review. *J Gastroenterol Hepatol* 2001; 16: 1086-92.
3. Chawla A, Maheshwari M, Parmar H. Obstructive jaundice in a case of portal hypertension. *Br J Radiol* 2003; 76: 667-9.
4. Sumathi B, Randhir J, Sekhar KS, Malathi S, Reddy DN, Jayanthi V. Portal biliopathy: case report. *J Assoc Physicians India* 2006; 54: 483-4.
5. Gaetano AM, Lafortune M, Patriquin H, Franco AD, Aubin B, Paradis K. Cavernous transformation of the portal vein: patterns of intrahepatic and splanchnic collateral circulation detected with doppler sonography. *Am J Roentegenol* 1995; 165: 1151-5.
6. Dhiman RK, Puri P, Chawla Y, Minz M, Bapuraj JR, Gupta S, et al. Biliary changes in extrahepatic portal venous obstruction: compression by collaterals or ischemic? *Gastrointest Endosc* 1999; 50: 646-52.
7. Malkan GH, Bhatia S J, Bashir K, Khemani R, Abraham P, Gandhi MS, et al. Cholangiopathy associated with portal hypertension: diagnostic evaluation and clinical implications. *Gastrointest Endosc* 1999; 49: 344-8.
8. Luqman Z, Khan M R, Alam M, Atiq M, Sophie Z. An analysis of surgical shunts for the management of Portal Hypertension at Aga Khan University Hospital. *J Ayub Med Coll Abbottabad* 2004; 16: 70-4.