



THE AGA KHAN UNIVERSITY

eCommons@AKU

Section of Gastroenterology

Department of Medicine

September 2009

Esophageal polypoidal mass: presentation of an uncommon pleomorphic carcinoma

Javed Yakoob
Aga Khan University

Z Abbas
Aga Khan University

Wasim Jafri
Aga Khan University

Najamul Sahar Azad
Aga Khan University

Follow this and additional works at: http://ecommons.aku.edu/pakistan_fhs_mc_med_gastroenterol



Part of the [Digestive System Diseases Commons](#), and the [Gastroenterology Commons](#)

Recommended Citation

Yakoob, J., Abbas, Z., Jafri, W., Azad, N. (2009). Esophageal polypoidal mass: presentation of an uncommon pleomorphic carcinoma. *Journal of the Pakistan Medical Association*, 59(9), 639-41.

Available at: http://ecommons.aku.edu/pakistan_fhs_mc_med_gastroenterol/16

Case Report

Esophageal polypoidal mass: presentation of an uncommon Pleomorphic carcinoma

Javed Yakoob, Zaigham Abbas, Wasim Jafri, Najamul Sahar Azad
Department of Medicine and Pathology, The Aga Khan University, Karachi, Pakistan.

Abstract

Pleomorphic carcinomas are primary malignant tumours that are known to arise in the lungs, pancreas, gall bladder and intestine. A patient with polypoid tumour of the esophagus is described in this report. The patient presented with dysphagia. Diagnostic and therapeutic intervention required endoscopic evaluation and treatment. Benign esophageal tumours are rarely seen and originate from the upper third of esophagus. We observed an esophageal tumour which was interpreted as spindle cell carcinoma of the esophagus that caused obstruction. We present the clinical picture and histopathological findings of the tumour. To our knowledge this is the first local report of spindle cell carcinoma occurring in the esophagus and

describes its endoscopic and histopathological features with distinctive biphasic morphology.

Introduction

Spindle-cell carcinoma is a malignant tumour accounting for 0.1%-1.5% of all esophageal tumours.^{1,2} It is composed of carcinomatous and sarcomatous components and has been reported to occur in the uterus, vagina, lungs, oral cavity, larynx, thyroid, urinary tract and esophagus. Microscopically, they are biphasic tumours composed of squamous cell carcinoma admixed with a spindle sarcoma-like stroma.³ On immuno-histochemical analysis, the spindle cells react with keratin or vimentin and with both in the same tumour as in our case.

Case Report

A seventy year old man presented to the gastroenterology clinic in May, 2008 with dysphagia for solids present for five years. He did not give history of anorexia and weight loss. He was a smoker but did not have a history of alcohol intake. On examination, his vital signs were intact and systemic examination was normal. An upper endoscopy (EGD) demonstrated at 24 centimeters (cm) from the incisors a 2.5 x 1.5 x 1.5 cm pedunculated polypoidal tumour with extensive ulceration of the mucosal surface with foci of haemorrhage and ulceration. The polypoid lesion was removed at endoscopy with a snare. Chest radiography and computed tomographic scan showed no pulmonary lesion. On histology, the lesion was predominantly composed of short fascicles of spindle shaped cells with variable amount of intervening collagen and multiple variable sized blood vessels (Figure-1). The

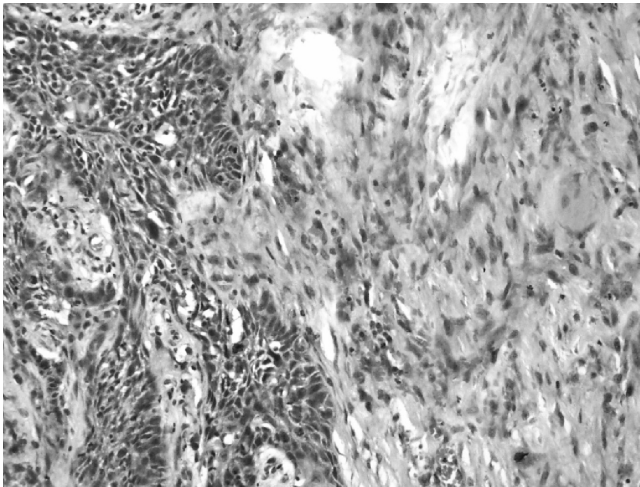


Figure-1: High power view of spindle cell carcinoma showing epithelial component with squamous differentiation and stromal component composed of spindle shaped cells having features of malignancy.

tumour cells had moderate to abundant eosinophilic cytoplasm and tapering cytoplasmic ends. The nuclei were round to oval showing coarse chromatin and prominent nucleoli. In areas marked nuclear atypia is appreciated. There was brisk mitotic activity with multiple atypical mitotic figures. Entrapped within these spindle cell areas, were multiple interconnecting lobules and nests of polygonal squamoid cells showing severe dysplasia and keratin pearl formation. There were areas showing invasion in the stroma by these squamous cells. Cystic degeneration of these epithelial nests was also noted. The lesion reached the painted margin of excision. Immunohistochemical profile of the tumour cells showed vimentin was positive in the spindle cell component, cytokeratin AE1/AE3 in epithelial component and cytokeratin 5/6 in epithelial

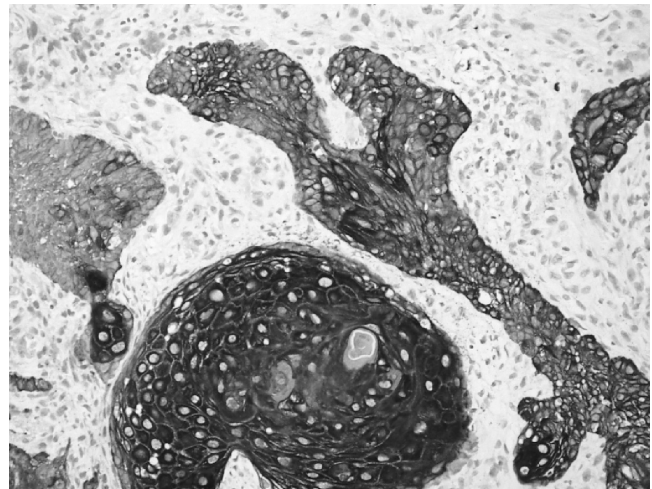


Figure-2: Cytokeratin AE1/AE3 showing positivity in the epithelial component.

component (Figure-2). One month later, an esophagogastrectomy was performed. Postoperative recovery was good. Two months later, the patient presented with bronchopneumonia. There was an atelectasis of the lower right pulmonary lobe due to an occlusion of the main right bronchus by a tumour mass. No further intervention followed. The patient died one month after the presentation of his symptoms. No autopsy was performed.

Discussion

The differential diagnosis of a large polypoid lesion of the esophagus in benign category includes fibrovascular polyp, pedunculated lipoma, myofibroma, and leiomyoma which may present as a polypoid mass. Among the malignant lesions, squamous cell carcinoma rarely presents as a polypoid mass.^{4,5} More frequently, adenocarcinoma of the esophagus arising from Barrettes mucosa may present as a solitary polypoid lesion or with a predominant polypoid component.⁶ Mesenchymal sarcomas such as leiomyosarcomas, fibrosarcoma, rhabdomyosarcoma, melanoma, oat cell carcinoma and lymphoma of the esophagus are rare causes of esophageal polypoid masses.⁷ While the lesions mentioned above may occasionally be polypoid masses, the spindle cell squamous cell carcinoma almost always is bulky and polypoid. Differentiation between various lesions may be difficult radiologically or endoscopically, almost always requiring histologic verification. This bulky intraluminal polypoid mass of the esophagus having a pedicle suggests that spindle cell carcinoma starting as a polypoid lesion which left long enough, will eventually grow to ulcerate and invade the esophageal wall. In terms of metaplastic potential, both the squamous cell and the spindle cell elements are capable of regional and distant dissemination.⁸ Micromorphologically,

the malignant spindle cell part usually occupies the overwhelming volume of the neoplasm. The prognosis of spindle cell carcinoma is considered to be equal to or worse than conventional squamous cell carcinoma.⁹

Pleomorphic giant cell carcinomas must be distinguished from malignant melanomas. In the esophagus, primary melanomas tend to be large stenosing, polypoidal, and are often focally ulcerated.¹⁰ They spread mainly in the submucosa. Numerous melanin deposits are usually observed but the melanoma cells may not contain melanin pigment. Moreover, neither melanosome nor HMB 45 expression was detected in the tumour. Pleomorphic giant cell carcinomas are usually a diagnostic dilemma, particularly when they occur in unexpected locations. Immunohistochemical study and ultrastructural examination are needed to demonstrate this. In conclusion, esophageal squamous cell carcinoma constitute majority of the esophageal malignancies but this is the first reported case of spindle cell carcinoma of

esophagus from our region.

References

1. Stout AP, Humphreys GH, Rottenberg LA. A case of carcinosarcoma of the esophagus. *Am J Roentgenol Radium Ther Nucl Med* 1949; 61:461-9.
2. Demarco AR, Leon W, Coleman WO, Welsch RA, Strug LH. Pseudosarcoma of the esophagus. *J Thorac Cardiovasc Surg* 1965; 49: 188-93.
3. Stout AP, Lattes R. Tumours of the Esophagus. *Atlas of Tumour Pathology*, section 5, Fascicle 20. Washington DC: Armed Forces Institute of Pathology 1957; pp 95-103.
4. Agha FP, Whitehouse WM. Carcinoma of the esophagus: its varied radiologic features. *Mt Sinai J Med* 1984; 51: 430-41.
5. Agha FP, Weatherbee L, Sams JS. Verrucous carcinoma of the esophagus. *Am J Gastroenterol* 1984; 79: 844-9.
6. Agha FP. Barrett carcinoma of the esophagus: clinical and radiographic analysis of 34 cases. *AJR Am J Roentgenol* 1985; 145: 41-6.
7. Agha FP, Schnitzer B. Esophageal involvement in lymphoma. *Am J Gastroenterol* 1985; 80: 412-6.
8. Olmsted WW, Lichtenstein JE, Hyams VJ. Polypoid epithelial malignancies of the esophagus. *AJR Am J Roentgenol* 1983; 140: 921-5.
9. Hyams VJ. Spindle cell carcinoma of the larynx. *Can J Otolaryngol* 1975; 4: 307-13.
10. Stranks GJ, Mathai JT, Rowe-Jones DC. Primary malignant melanoma of the esophagus: case report and review of surgical pathology. *Gut* 1991; 32: 828-30.