

East African Medical Journal Vol. 85 No. 6 June 2008

PRIMARY CEREBRAL ANGITIS OF THE CENTRAL NERVOUS SYSTEM: CASE REPORT

S. Das, MBBS, MRCP, MD, Registrar, J.O. Jowi, MBChB, MMed, Dip. Clin. Neurol (Queen Square London), Senior Lecturer, Department of Medicine, K. Hameed, FCPS, Chairman and Associate Professor and F.S. Rana, MBChB, MMed (Path), Associate Professor, Department of Pathology, Aga Khan University Hospital, Nairobi, P.O. Box 30270-00100, Nairobi, Kenya

Request for reprints to: Dr. S. Das, Department of Medicine, Aga Khan University Hospital, Nairobi, P.O. Box 30270-00100, Nairobi, Kenya

PRIMARY CEREBRAL ANGITIS OF THE CENTRAL NERVOUS SYSTEM: CASE REPORT

S. DAS, J.O. JOWI, K. HAMEED and F.S. RANA

SUMMARY

We report a case of a 28 year old female who presented with variedly progressive stroke like illness and raised intracranial pressure. Brain MRI scans revealed pericallosal and periventricular hyperintensities with oedema. Various medications like intravenous immunoglobulin, antibiotics, acyclovir, methyl prednisolone and management for raised intracranial pressure were instituted. She rapidly deteriorated and died on tenth hospital day. Only at autopsy was the diagnosis of primary angitis of central nervous system established.

INTRODUCTION

Primary angitis of central nervous system (PACNS) is a rare inflammatory condition of small and medium sized vessels of the brain and spinal cord (1). There are less than 100 cases described in English literature (1). European survey published in 2002 confirmed the anticipated low frequency of the disease (3). The challenge in diagnosis of PACNS is due to lack of specific signs and symptoms, inaccessibility of the end-organ for pathologic examination, lack of efficient non-invasive diagnostic tests and relative rarity of the diseases (4). In order to make a diagnosis secondary causes of vasculitis should be excluded (1,2). The disease can be life threatening unless appropriate therapy is started immediately (1).

CASE REPORT

A 28 year old African female, previously well reported to Aga Khan University Hospital, Nairobi (AKUH) with five days history of episodic weakness of limbs, visual obscurations lasting for about 10 minutes occurring two to three times a day. There was no history suggestive of increased intracranial pressure. She was a non-smoker, did not have any

history of alcohol intake or illicit drug use. Her vital signs were stable. On neurological examination her higher functions were normal with intact memory. Fundoscopic examination was normal. No cranial nerve palsy was noted. There was left lower limb weakness; power grade 4 (MRC scale) with normal deep tendon reflexes. The other limbs were of normal power. Sensation was normal. There were no clinical signs of meningitis. The diagnosis of possible recurrent TIA or cerebral vasculitis was made and low dose aspirin was started.

Various investigations were done, which included: Full-haemogram, urea, creatinine, electrolytes, liver function tests, random blood sugar, electrocardiogram, echo-cardiogram of heart, urine analysis; all results were normal. HIV, VDRL and TPHA, antinuclear antibody and antiphospholipid antibody testing were negative. Brain CT scan showed focal cerebritis. Cerebral fluid showed 140rbcs/ml, less than 5wbcs/ml, biochemistry, microscopy including viral markers for Epstein barr virus, herpes simplex and zoster virus, and cytomegalovirus virus were negative. In view of the above findings, acyclovir 750mg IV given eight hourly was commenced empirically for possible viral encephalitis.

On the second day of admission weakness progressed to all four limbs but was more marked on the left side. Cervical spine MRI scan was normal. Brain MRI scan showed hyper intensities in pericallosal and right periventricular areas in the FLAIR sequence which was non enhancing after the contrast. Intravenous methyl-prednisolone 1gm IV given once daily was therefore commenced.

On third day, the patient further deteriorated developed urinary incontinence, 3rd cranial nerve palsy and signs of increased intracranial pressure (ICP). She was transferred to intensive care unit and managed as per increased ICP protocol. IV immunoglobulin 20gms per day for five days was started considering possibility of cerebral vasculitis or acute disseminated encephalomyelitis. Repeat brain CTscan showed right MCA infarct and oedema of right cerebral hemisphere compressing brainstem. Carotid CTangiogram showed marked narrowing of right MCA. Despite all supportive measures she deteriorated and died on tenth day of admission.

A full autopsy was performed. The brain showed flattening of gyri, on section petechial haemorrhages and focal infarcts were seen. The leptomeningeal arteries were thickened and prominent. Lungs showed features of acute respiratory distress syndrome as the terminal event. All other organs were normal on gross morphology. Microscopy showed focal infarcts in the white matter (Figure 1), segmental inflammation, mainly by lymphocytes and few neutrophils and fibrinoid necrosis (Figure 2) of leptomeningeal and parenchymal blood vessels. There was marked reactive astrocytosis (Figure 3).

Figure 1

Infarct (arrow) surrounding inflamed vessel (H/E stain x40)

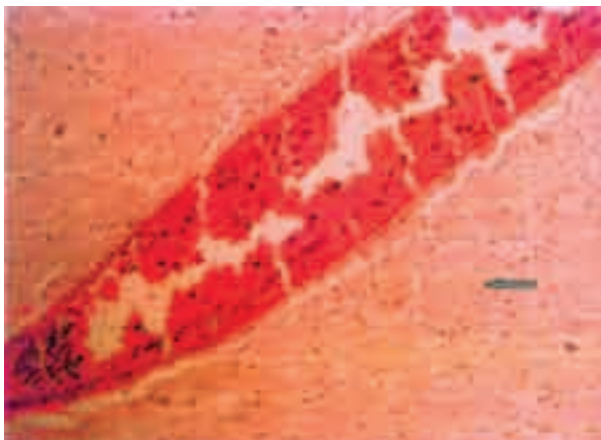

Figure 2

Fibrinoid necrosis and inflammation (arrows) of leptomeningeal vessels (H/E stain x40)

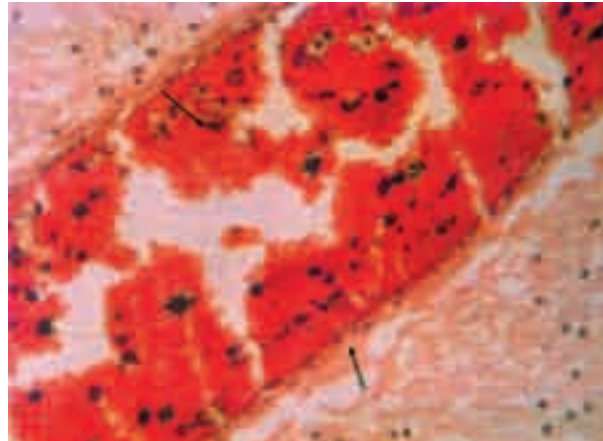



Figure 3

Reactive astrocytosis (thick arrow) and infarct (thin arrow) (H/E stain x40)



DISCUSSION

Primary angitis of central nervous system (PACNS) is an uncommon condition which can occur at any age, though it typically affects patients in the 4th or 5th decades of life (4). Onset of the disease is highly variable (4). The aetiology and the pathogenesis remains unknown (2). Though the clinical presentation can vary widely; three main clinical patterns have been described. First pattern is acute or sub acute encephalopathy progressing to drowsiness and coma, second pattern is symptoms suggestive of intracranial mass lesion, and the last one resembling atypical multiple sclerosis (3). In this multiple sclerosis-plus type, hemispheric stroke episodes have been described.

Our patient presented with features of atypical multiple sclerosis-like findings which progressed rapidly to hemispheric stroke like features with increased intracranial pressure. In PACNS the CSF findings are typically suggestive of aseptic meningitis. Normal spinal fluid findings has a strong but not absolute negative predictive value for further invasive studies for PACNS (4). Our patient had CSF with raised red blood cells count; other parameters being normal therefore empirical acyclovir treatment was given. Brain CT scan shows multiple, bilateral infarcts mostly in deep white matter and supra-tentorial in location (5). Multiple sub-cortical infarcts are classical MRI findings (6). Cerebral angiogram alone cannot exclude or establish a diagnosis of isolated PACNS. However, the characteristic appearance is a pattern of symmetrical narrowing or beading with multiple areas of involvement (2). Sensitivity for the different diagnostic modalities are CT 33–50%, MRI scan 50–100%, Cerebral angiogram 33–100% (4). Radiological investigations in our patient did not help us much in diagnosis. Brain biopsy remains the gold standard for the diagnosis (4) with sensitivity of 75%. It has its technical limitations and the sensitivity is low because of the skipped lesions (4). Histologically there is segmental inflammation and fibrinoid necrosis of leptomeningeal and parenchymal blood vessels (2,6). Surrounding brain tissue may show ischaemic necrosis, evolving haemorrhagic infarcts and reactive astrocytosis (2). Review of literature indicates that there is a predilection for leptomeningeal blood vessels though any part of brain and spinal cord can be affected (2). Lucas *et al* (7) describes a similar case and recommends angiography and a combined leptomeningeal and cortical biopsy should be performed immediately on suspicion of cerebral vasculitis. We set out to exclude various aetiology including most of the infective, neoplastic, autoimmune causes from the initial investigations. It was a diagnostic challenge because of the rarity of condition. Our final diagnosis was from the autopsy results.

Though there is great variation in clinical practice for management because of the rarity of the condition the consensus of opinion is high dose IV corticosteroids. Pulsed cyclophosphamide should be added to those who do not respond rapidly to initial steroids. Arthritis and rheumatism council recommends combined steroid and pulsed cyclophosphamide therapy because of high risk of relapse and long term complications (2). The patient presented was given high dose intravenous steroid therapy. May be addition of cyclophosphamide would have been of help.

In our opinion when the neurological findings remain unexplained, secondary causes of vasculitis should have been excluded; diagnosis of PACNS should be highly suspected and investigated appropriately for early diagnosis and treatment.

REFERENCES

1. Kurihara, T. Isolated angitis of the central nervous system: Early diagnosis and treatment. *Intern. Med.* 2005; **44**: 883-885.
2. Rehman, H.U. Primary angitis of the central nervous system. *J. R. Soc. Med.* 2000; **93**: 586-588.
3. Scolding, N.J., Wilson, H., Hohlfeld, R., *et al.* The recognition, diagnosis and management of cerebral vasculitis: A European survey. *Eur. Neurol.* 2002; **9**: 343-347.
4. Singhanian, S., Jethava, Y., Korvi, D., *et al.* A young lady with abnormal behaviour and stroke: *J. Indian Rheumatol.* 2003; **11**: 16- 18.
5. Greenan, T.J., Grossman, R.I. and Goldberg H.I. Cerebral vasculitis: MR imaging and angiographic correlation. *Radiol.* 1992; **182**: 65-72.
6. Desai S.B. CNS vasculitis—not an uncommon entity. *Ind. J. Radiol. Imag.* 2005; **15**: 419-420.
7. Lucas, C., Katty, K. and Christian, B. Primary angitis of central nervous system presenting with sub acute and fatal course of disease: A case report: *BMC. Neurol.* 2005; **5**: 16.