



THE AGA KHAN UNIVERSITY

eCommons@AKU

Section of Paediatric Surgery

Department of Surgery

2005

Bacillus calmette-guerin (BCG) lymphadenitis: Changing trends and management

Zafar Nazir

Aga Khan University, zafar.nazir@aku.edu

Saqib Hamid Qazi

Aga Khan University, saqib.qazi@aku.edu

Follow this and additional works at: https://ecommons.aku.edu/pakistan_fhs_mc_surg_paediatr



Part of the [Pediatrics Commons](#), and the [Surgery Commons](#)

Recommended Citation

Nazir, Z., Qazi, S. H. (2005). Bacillus calmette-guerin (BCG) lymphadenitis: Changing trends and management. *Journal of Ayub Medical College Abbottabad*, 17(4), 16-18.

Available at: https://ecommons.aku.edu/pakistan_fhs_mc_surg_paediatr/6

BACILLUS CALMETTE-GUERIN (BCG) LYMPHADENITIS- CHANGING TRENDS AND MANAGEMENT

Zafar Nazir, Saqib Hamid Qazi

Section of Pediatric Surgery, Department of Surgery, The Aga Khan University Hospital, Karachi, Pakistan

Background: Bacillus Calmette-Guérin (BCG) vaccination is performed as a part of expanded Programme of Immunization (EPI). Suppurative lymphadenitis is the common complication of BCG vaccination. The optimum treatment for this complication is debated. **Methods:** All cases of BCG lymphadenitis presenting to pediatric surgical service over a 17-year study period were reviewed to determine the optimum treatment for this problem. **Results:** Sixty children were referred for the management of BCG lymphadenitis during the study period. Most patients (n=43) presented during 1988 and 1990. Children were healthy and received BCG (Pasteur strain) vaccination at EPI during first 2 months of life. Initially all the patients received medical treatment with anti-tuberculous drugs for one to nine months. Fifty-two children who presented with large (~ 3cm) fluctuant lymph nodes, required a surgical procedure to avoid spontaneous rupture and sinus formation (Group A), whereas medical treatment was effective in five out of eight patients presenting with small (~ 1 cm) nodes (Group B). **Conclusions:** Medical treatment with antituberculous drugs is not effective to treat BCG lymphadenitis, when the involved lymph nodes are around 3.0 cm and have developed fluctuation and inflammation of over lying skin.

Keywords: Vaccination, BCG vaccine, Lymph node, Lymphadenitis

INTRODUCTION

Bacillus Calmette-Guérin (BCG) is a live attenuated vaccine derived from a strain of *Mycobacterium bovis*. The world health organization (WHO) has recommended BCG vaccination as a part of the global expanded program for immunization (EPI). The efficacy of currently available BCG vaccines ranges from 60 to 90%.^{1,2} BCG vaccine is a safe vaccine, but a number of complications such as localized ulceration, regional lymphadenitis, osteomyelitis, lupoid reactions, eczema vaccinatum, hypertrophic scars and keloid formation, disseminated infection and death follow vaccination.^{1,6} The incidence of regional suppurative lymphadenitis ranges from 0.1 to 38 per 1000.^{1,3,8} There appears to be no agreement on the treatment of this relatively common complication. Opinions differ widely, from no treatment to surgical drainage to administration of antituberculous drugs. The beneficial effects of these therapies are controversial.^{2,3} The present report describes sixty patients who developed regional lymphadenitis following BCG vaccination and were referred to pediatric surgical service at the Aga Khan University hospital (AKUH), Karachi, from July 1986 to June 2003. The emphasis is on efficacy of different therapeutic approaches.

MATERIAL AND METHODS

Medical records were reviewed for year of presentation, age at vaccination and presentation to AKUH, sex, place of vaccinations, interval between vaccinations and development of lymphadenitis, clinical findings on physical examinations, hematological, microbiological and histopathological data, chest radiographs, treatment and outcome.

Fifty-two children underwent a surgical procedure (Group A) whereas eight patients received medical treatment only (Group B). Indications of surgery include failure of medical treatment, large (~ 3.0 cm) lymph nodes, and development of fluctuation and inflammation of overlying skin. The surgical procedure was performed under general anaesthesia. Excochleation of all the necrotic tissue and excision of enlarged lymph nodes was performed through a skin crease incision. After hemostasis the wound was closed in subcuticular fashion using 5/0 Vicryl suture after leaving a Penrose drain. A pressure dressing was applied for 48- hours. All the surgical specimens were sent to microbiology; for a routine and AFB culture on Löwenstein Jensen agar, and for histopathological evaluation.

RESULTS

The number of patients having BCG lymphadenitis has decreased after 1991. Forty-three patients (71%) presented during 1988 and 1990 (Figure 1). Most patients were full-term (n=57) and none had clinical evidence of immune deficiency. Their ages ranged from 2.5 months to 6 years (mean 7 months), and the male to female ratio was 2.9:1. The patients received vaccination within first two months of life at EPI centers with Pasteur strain of BCG vaccine. Lymphadenitis developed within 6-months in 55 patients (92%), whereas five children developed lymphadenopathy 1 to 5 years after the vaccination. The localization of lymphadenopathy varied according to vaccination site; left axilla (n=57), left supraclavicular region (n=2) and right inguinal region (n=1). Three patients were anemic (hematocrit <30%) and two had raised ESR (>20 mm/hr). Chest

radiographs available in 25 patients did not revealed abnormality. The size of enlarged lymph nodes varied from 1.5cm to 5.0cm (mean 3.5cm). At the time of referral, all the patients were receiving medical treatment; isoniazid (n=52), rifampicin (n=50), and erythromycin (n=8) for one to nine-months (mean 3-months) and 20 patients had developed discharging sinus following needle aspiration of fluctuant lymph nodes. The results are summarized in Figure 2

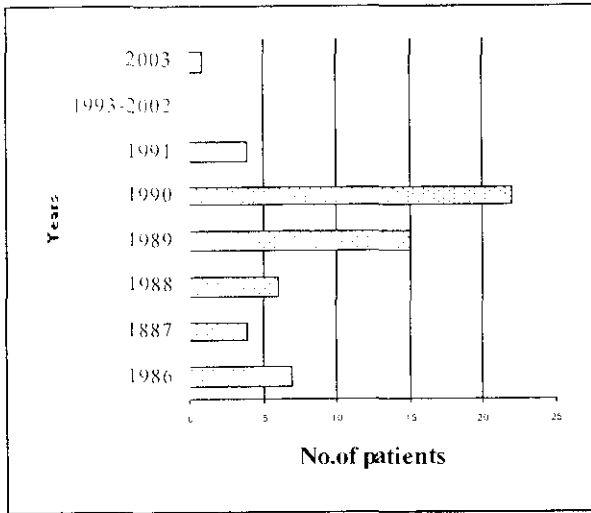


Figure 1: BCG lymphadenitis at AKUH from 1986-2003

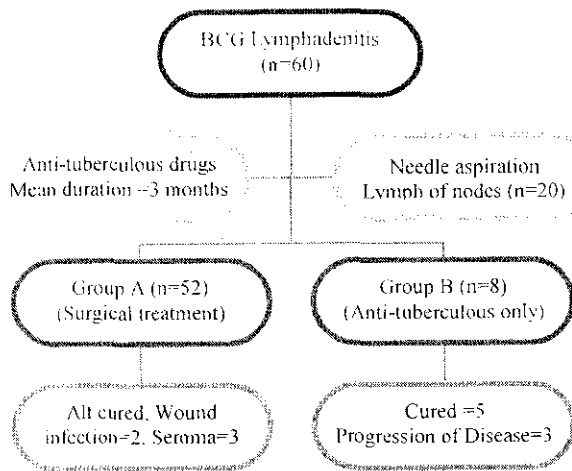


Figure 2: Management of BCG lymphadenitis at AKUH

Group A

Fifty-two patients who presented with large fluctuant lymph nodes (~3.0 cm) with overlying skin change and discharging sinus (n=20) underwent a surgical procedure (Figure 3). Histopathological evaluation of extirpated nodes showed caseous necrosis and granuloma formation, a finding consistent with tuberculosis. Microbiology revealed growth of mycobacterium bovis (n=2), staphylococcus aureus

(n=4), staphylococcus epidermatitis (n=3), pseudomonas (n=1) and Klebsiella spp. (n=1). Post operatively all the patients were prescribed antituberculous treatment for 6 weeks. Nine patients though advised did not take anti-tuberculosis drugs in postoperative period for various reasons. Two patients had superficial wound infections, and three developed seroma. All patients recovered and did not showed evidence of lymphadenitis or systemic tuberculosis on 6-18 months follow-up.

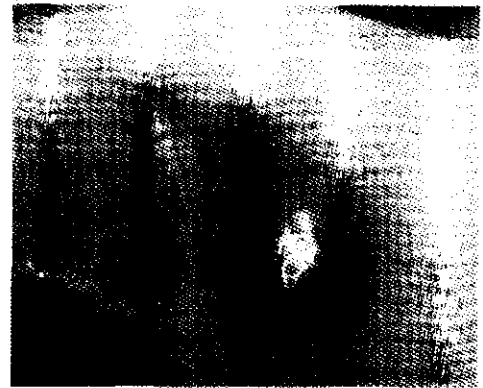

Figure 3: Suppurative BCG lymphadenitis in right axillary region. The lymph node measures 5 cm in diameter, and is fluctuant in centre and the overlying skin is inflamed

Group B

Eight patients received medical treatment only. At the time of referral, these patients had smaller lymph nodes (~1.5cm), and the overlying skin was normal. Five patients showed resolution of lymphadenopathy after 6 months of treatment. Three patients did not respond, continued to have progressive disease, and underwent surgery at other medical facility.

DISCUSSION

Intradermal vaccinations with BCG give rise to a classic primary complex that consists of a cutaneous nodule at the site of injection and swelling of the regional lymph nodes. This is usually self-limiting and requires no treatment. However, in a small proportion of subjects this reaction to BCG vaccine is excessive and results in suppurative lymphadenitis. BCG lymphadenitis is commonly observed two to eight weeks following vaccination, although there can be a delay up to 8 months or even more as seen in this study.^{1,2,7,8} The involved nodes are usually ipsilateral to the vaccination site. A number of factors such as age of the child, technique of vaccination, the BCG strain, the dose, potency, viability and immunogenicity of the vaccine and prior exposure to mycobacterial antigen are implicated in the pathogenesis of lymphadenitis.^{1,7,8} The younger children are more commonly affected. The studies on these children have failed to demonstrate significant nutritional or immune deficiency.¹ Epidemics of BCG lymphadenitis were

reported in many countries during 1988 to 1990 as seen in this study.^{1, 9-11} Analysis of all these epidemics has revealed that BCG lymphadenitis is an exaggerated response to more immunogenic vaccines. All of these epidemics occurred when a BCG vaccine containing more immunogenic strain was introduced in the immunization schedule.^{1,9-11} The maintenance of different laboratories for the manufacturing of BCG vaccine has resulted in a variety of BCG strains with slightly differing geno and phenotypic properties. The cellular components of a particular vaccine not only influence the outcome of immunization but also post vaccination complications.^{1,9} Thus the protective properties and adverse effects caused by different BCG strains may vary.¹ Moreover, inappropriate storage, wrong method of administration of vaccine and secondary invasion of immunization site by the pyogenic organisms may contribute to the development of BCG lymphadenitis in the developing countries.

The reported treatment of BCG lymphadenitis varies from doing nothing to medical treatment, or surgical excision of involved lymph nodes.¹²⁻¹⁴ BCG is sensitive to isoniazid, rifampicine and erythromycin *in vitro*, but the treatment of BCG lymphadenitis with these agents is not effective, once the lymph nodes has reached a certain size (>3.0 cm), and has developed fluctuation and inflammation of overlying skin.^{7,8,15} Medical treatment may be effective in early stage of the disease.^{8,10,12-14} With a relapse rate of 14% and risk of fistulation, needle aspiration of caseating lymph nodes is not an alternative to surgery.^{10, 17} Surgical excision is a treatment of choice for fluctuant, enlarged lymph nodes where the inflammatory process has involved or perforated the skin.^{7, 8, 10} It can prevent development of persistent discharging sinus. It is important to excise all accessible nodes. Wound healing after excision is usually excellent. A Penrose drain in the residual space after the excision of axillary lymph nodes can prevent seroma. Although recommended, postoperative anti-tuberculosis therapy seems to be unnecessary.¹⁰ Nine patients in this series who did not take anti-tuberculosis drugs postoperatively had an uneventful healing and outcome. A prophylactic dose of broad-spectrum antibiotic may prevent wound infections as significant number of patients in this series have grown pyogenic organism from the excised lymph nodes.

In conclusion, suppurative lymphadenitis is a common complication of BCG vaccination and is probably is secondary to introduction of more immunogenic vaccines. Medical treatment is usually ineffective once the enlarged lymph nodes have

developed fluctuation and inflammation of overlying skin. It is important to develop uniform system to standardize BCG vaccines and exercise restrain in switching the preparations of BCG vaccine in the developing countries, as this could influence the compliance to EPI programmes in these countries.¹⁸

REFERENCES

1. Milstien JB, Gibson JJ. Quality control of BCG vaccine by WHO: a review of factors that may influence vaccine effectiveness and safety. Bulletin of the World Health organization 1990; 68:93-108.
2. Bannon MJ. BCG and tuberculosis. Arch Dis Child 1999; 80: 80-3.
3. Karnak I, Senocak ME, Buyukpamukcu N, Gocmen A. Is BCG vaccine innocent? Pediatr Surg Int 1997; 12: 220-223.
4. Sadeghi E, Kumar PV. Eczema vaccinatum and post BCG adenitis. Tubercle 1990; 71:145-6.
5. Peltola H, Salmi I, Vahvanen V. BCG vaccination as a cause of osteomyelitis and subcutaneous abscess. Arch Dis Child 1984; 59:157-61.
6. Kroger L, Brander E, Korppi M, Wasz-Hockert O, Backman A, Kroger H et al. Osteitis after newborn vaccination with three different Bacillus Calmette-Guerin vaccines: twenty-nine years of experience. Pediatr Infect Dis J 1994;12:113-6.
7. Aggarwal NP, Kallan BM, Grover PS, Aggarwal M. Clinico-Excisional study of lymphadenitis following BCG vaccination. Indian J Pediatr 1990;57:585-6.
8. Merry C, Fitzgerald RJ. Regional lymphadenitis following BCG vaccination. Pediatr Surg Int 1996;11:269-71.
9. Praveen KN, Smikle MF, Prabhakar P, Pande D, Johnson B, Ashley D. Outbreak of Bacillus Calmette-Guerin Associated lymphadenitis and abscesses in Jamaican children. Pediatr Infect Dis J 1990;9:890-3.
10. Hengster P, Solder B, Fille M, Menardi G. Surgical treatment of Bacillus Calmette-Guerin Lymphadenitis. World J Surg 1997; 21:520-3.
11. Hengster P, Schuapka J, Fille M, Menardi G. Occurrence of suppurative lymphadenitis after a change of BCG vaccine. Arch Dis Child 1992;67:952-5.
12. Close GC, Nasiro R. Management of BCG adenitis in infancy. J Trop Pediatr 1985;31:286-9.
13. Murphy PM, Mayers DL, Broek NF, Wagner KF. Cure of Bacilli Calmette - Guerin vaccination abscess with erythromycin. Rev Infect Dis 1989; 11:335-7.
14. Hanley SP, Gumb J, Macfarlane JT. Comparison of Erythromycin and Isoniazid in treatment of adverse reaction to BCG vaccination. Br Med J 1985; 290:970-3.
15. Caglayan S, Yegin O, Kayran K, Timocin N, Kasirga, Gun M. Is medical therapy effective for regional lymphadenitis following BCG vaccination? AJDC 1987; 141:1213-4.
16. Caglayan S, Arikian A, Yaprak I, Aksoz K, Kansoy S. Management of suppurative in regional lymph nodes secondary to BCG vaccination. Acta Paediatr Jpn 1991; 33: 699-702.
17. Banani SA, Alborzi A. Needle aspiration for suppurative post-BCG adenitis. Arch Dis Child 1994; 71: 446-7.
18. Rafi S, Ahmed A, Ramazan M, Billo AG. BCG lymphadenitis: A study of knowledge, attitude and practice of mothers including effect on completion vaccination schedule. J Coll Physicians Surg Pakistan 1994; 4: 80-2.

Address For Correspondence:

Dr. Zafar Nazir, Section of Pediatric Surgery, Department of Surgery, The Aga Khan University, P.O. Box 3500, Stadium Road, Karachi 74800, Pakistan. Fax: (92 21) 493-2095

Email: zafar.nazir@aku.edu