



THE AGA KHAN UNIVERSITY

eCommons@AKU

Section of General Surgery

Department of Surgery

2012

Duhamel's procedure for adult hirschsprung's disease

Mehreen Adhi
Aga Khan University

Salma Khan
Aga Khan University

Hasnain Zafar
Aga Khan University, hasnain.zafar@aku.edu

Muhammad Arshad
Aga Khan University, arshad.muhammad@aku.edu

Follow this and additional works at: https://ecommons.aku.edu/pakistan_fhs_mc_surg_gen



Part of the [Surgery Commons](#)

Recommended Citation

Adhi, M., Khan, S., Zafar, H., Arshad, M. (2012). Duhamel's procedure for adult hirschsprung's disease. *Journal of the College of Physicians and Surgeons Pakistan*, 22(6), 395-397.
Available at: https://ecommons.aku.edu/pakistan_fhs_mc_surg_gen/2

Duhamel's Procedure for Adult Hirschsprung's Disease

Mehreen Adhi, Salma Khan, Hasnain Zafar and Muhammad Arshad

ABSTRACT

An adult presented with chronic constipation and abdominal mass. Clinical features, abdominal radiographs and barium enema revealed features consistent with Hirschsprung's disease. Full-thickness rectal biopsy was planned, but patient was lost to follow-up and presented 3 years later with intestinal obstruction. Exploratory laparotomy with resection of affected sigmoid colon and end colostomy were performed. Sequential rectal biopsies were obtained during the procedure to confirm the diagnosis. Later, Duhamel's procedure with a diverting loop ileostomy was successfully performed. Ileostomy reversal was done thereafter. There was complete resolution of symptoms and dramatic improvement in bowel function.

Key words: *Adult Hirschsprung's disease. Adult. Rectal biopsy. Duhamel's procedure. Abdominal mass. Chronic constipation.*

INTRODUCTION

Hirschsprung's disease (HD) is a congenital aganglionosis of submucosal and myenteric neural plexuses, principally affecting distal sigmoid colon and rectum.¹ It is usually recognized in first few years of life, but can occasionally be encountered in adults as misdiagnosed cause of refractory constipation.² The term "Adult Hirschsprung's Disease" has been arbitrarily applied to cases in which patient is more than 10 years of age when diagnosis is first established.^{1,2} The first well-documented case of Adult HD was reported in 1950s by Rosin.¹ In these cases, disease may be of milder form and may go unrecognized, until the proximal colon can no longer propel faeces distally, leading to faecal retention and/or intestinal obstruction.¹ These patients usually have typical medical history of life-long chronic constipation, with very frequent use of enemas and cathartics for relief of constipation since early childhood.¹⁻³ Definitive diagnosis is established on full-thickness rectal biopsy; barium enema and manometric studies being useful investigations.¹ Duhamel's procedure is recognized as most reliable and safe surgical procedure for treatment of Adult HD with excellent long-term functional outcome.^{1-5,9}

We report a case of adult Hirschsprung's disease successfully treated with Duhamel's procedure.

CASE REPORT

A 17-year-old male presented in outpatients' clinic at the Aga Khan University Hospital (AKUH), Karachi, Pakistan, in October 2003, with abdominal mass for one

year and chronic constipation since early childhood, requiring frequent use of enemas for relief. He had been seen by many doctors for evaluation of chronic constipation during early childhood and thereafter, but no diagnosis could be established. He was therefore, admitted at AKUH for evaluation. On examination, abdomen was distended, and a firm, non-tender, hemispherical mass measuring 12 cm x 14 cm was palpable in umbilical and hypogastric region. Bowel sounds were absent.

Plain abdominal radiograph revealed a well circumscribed ovoid mass in the left hemi-abdomen, with well-defined margins. Barium enema study revealed narrowed distal sigmoid colon with significant proximal sigmoid dilatation with faecal loading. A computed tomographic scan confirmed severe colonic dilatation with extensive faecal loading. At this stage, the cause of chronic constipation was obscure. However, clinical features, radiographs and barium enema studies were consistent with Hirschsprung's disease. Therefore, with a provisional diagnosis of HD, faecal washout with full-thickness rectal biopsy was planned. However, patient was lost to follow-up for 3 years.

In July 2007, patient presented with absolute constipation, non-bilious vomiting, abdominal pain and distension in the emergency room. On examination, the abdomen was distended, diffusely tender and a firm, hemispherical mass was palpable in umbilical and hypogastric region. Bowel sounds were absent. Digital rectal examination revealed empty rectum. Plain abdominal radiographs re-demonstrated very large descending and sigmoid colon with extensive faecal loading (arrow, Figure 1). Patient was kept on low-volume nasogastric suction and enemas to relieve constipation.

Once constipation was relieved, exploratory laparotomy with resection of affected sigmoid colon, and end colostomy were performed. A huge phytobezoar

Department of Surgery, The Aga Khan University Hospital, Karachi.

Correspondence: *Dr. Salma Khan, Resident, Department of Surgery, Room No. 218, Women Residency, The Aga Khan University Hospital, Stadium Road, Karachi-74800.*

E-mail: dr_salmakhan@yahoo.com

Received December 08, 2010; accepted December 19, 2011.

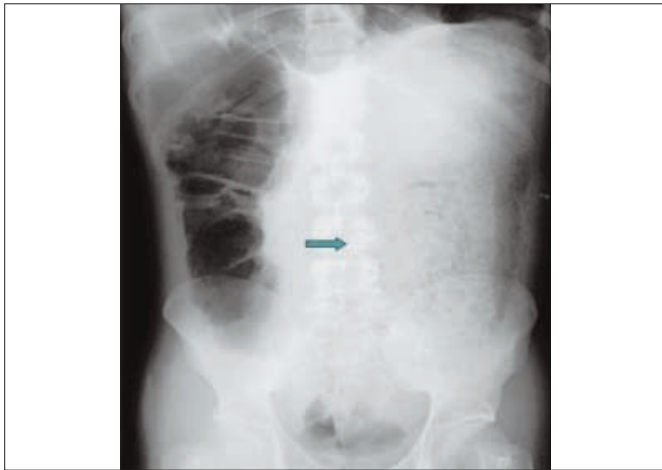


Figure 1: Plain abdominal radiograph illustrating a large descending and sigmoid colon with extensive faecal loading (arrow).

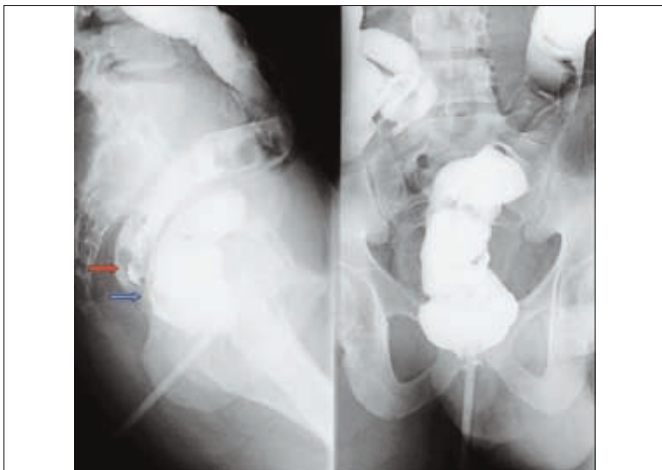


Figure 2: Barium enema study illustrating an intact rectal pouch (blue arrow) and anastomosis (red arrow) with no evidence of leakage.

measuring 15 cm x 12 cm was found in the left hypochondrium. An intussusception was noted in proximal jejunum, which was reduced. Sequential rectal biopsies were obtained during the procedure, which revealed absence of ganglion cells in affected segments, thus confirming the diagnosis of HD. Two months later, Duhamel's procedure with a diverting loop ileostomy was performed successfully.

Eight weeks following Duhamel's procedure, a barium enema study revealed an intact rectal pouch (blue arrow; Figure 2), with no evidence of leakage from either the rectal pouch or anastomosis (red arrow; Figure 2). Thus, diverting loop ileostomy was successfully reversed. Sigmoidoscopy and anal dilatation were also performed.

Patient was followed-up weekly initially, and monthly thereafter. At the time of last follow-up 3 years after the procedure, patient had no bowel complaints and reported exceptional improvement in bowel function and quality of life.

DISCUSSION

The diagnosis of Hirschsprung's disease in adults is much more challenging than in infants owing to rarity of the disease, and higher incidence of short/ultra-short segment aganglionosis in adults.^{1,2} A typical adult patient with HD has history of long-term constipation since infancy or early childhood; other symptoms include abdominal pain/discomfort and distention.^{1,2}

There is no obvious best choice of surgical procedure for Adult HD, and surgical outcome depends as much on the skills of multiple surgeons involved, as on chosen surgical procedure involving variety of techniques.⁶ Principal surgical procedures for Hirschsprung's disease have been described by Soave and Duhamel.^{7,8}

Duhamel's recto-rectal pull-through procedure has excellent results in adult patients with much lower incidence of postoperative complications.^{6,8} The primary complication is anastomotic leakage,⁶ leading to fistula or abscess formation. This procedure also has advantage of minimal pelvic dissection.⁶ The literature concentrating on adult follow-up of patients with HD who underwent Duhamel's procedure is scarce, and it has been reported that long-term outcome is quite variable, and that functional outcome improves as duration of follow-up increases.^{4,5} Duhamel's procedure is most widely accepted surgical procedure, provides better results in adult HD and is also associated with lower post-operative morbidity rates.¹⁻⁵

In this case, clinical features were similar to those reported in literature. It is still unclear whether adult HD is due to failure of diagnosis when patients present with chronic constipation in early childhood, or in fact a late-onset disease.^{1-3,9} Of note is that the literature reveals that most patients diagnosed with adult HD fall under the former category.^{1-3,9}

In addition to refractory long-standing constipation, our patient also presented with abdominal distension, and a firm, hemispherical abdominal mass. Duhamel's procedure was chosen over other procedures described in literature due to its widely accepted, good long-term functional outcome and much lower incidence of postoperative complications. More importantly, it also meant minimal pelvic dissection to be done in a young male patient, consequently sparing pelvic nerves. The outcome of Duhamel's procedure was excellent in our patient with complete resolution of symptoms and dramatic improvement in bowel function.

REFERENCES

1. Chen F, Winston JH 3rd, Jain SK, Frankel WL. Hirschsprung's disease in a young adult: report of a case and review of the literature. *Ann Diagn Pathol* 2006; **10**:347-5.
2. Miyamoto M, Egami K, Maeda S, Ohkawa K, Tanaka N, Uchida E,

- et al.* Hirschsprung's disease in adults: report of a case and review of the literature. *J Nippon Med Sch* 2005; **72**:113-20.
3. Vanoorbeek J, Kint M, Yvergnaux JP. Hirschsprung's disease in adults: the Duhamel procedure. *Acta Chir Belg* 2004; **104**: 304-8.
 4. Livaditis A. Hirschsprung's disease: long-term results of the original Duhamel operation. *J Pediatr Surg* 1981; **16**:484-7.
 5. Bjornland K, Diseth TH, Emblem R. Long-term functional, manometric and endosonographic evaluation of patients operated upon with the Duhamel's technique. *Pediatr Surg Int* 1998; **13**:24-8.
 6. Wheatley MJ, Wesley JR, Coran AG, Polley TZ. Hirschsprung's disease in adolescents and adults. *Dis Colon Rectum* 1990; **33**: 622-9.
 7. Soave F. Hirschsprung's disease: a new surgical technique. *Arch Dis Child* 1964; **39**:116-24.
 8. Duhamel B. Retrorectal and transanal pull through procedure for the treatment of Hirschsprung's disease. *Dis Colon Rectum* 1964; **7**:455-8.
 9. Barnes PR, Lennard-Jones JE, Hawley PR, Todd IP. Hirschsprung's disease and idiopathic megacolon in adults and adolescents. *Gut* 1986; **27**:534-41.

.....★.....