



THE AGA KHAN UNIVERSITY

eCommons@AKU

---

Department of Radiology

Medical College, Pakistan

---

April 2011

# Goldston syndrome

Zainab Hussain  
*Aga Khan University*

Imrana Masroor  
*Aga Khan University*

Qurrat-ul-Ain Haider  
*Aga Khan University*

Tariq Alam  
*Aga Khan University*

Follow this and additional works at: [http://ecommons.aku.edu/pakistan\\_fhs\\_mc\\_radiol](http://ecommons.aku.edu/pakistan_fhs_mc_radiol)



Part of the [Nephrology Commons](#), and the [Radiology Commons](#)

---

## Recommended Citation

Hussain, Z., Masroor, I., Haider, Q., Alam, T. (2011). Goldston syndrome. *Journal of the College of Physicians and Surgeons Pakistan*, 21(4), 242-244.

**Available at:** [http://ecommons.aku.edu/pakistan\\_fhs\\_mc\\_radiol/2](http://ecommons.aku.edu/pakistan_fhs_mc_radiol/2)

# Goldston Syndrome

Zainab Hussain, Imrana Masroor, Qurrat-ul-Ain Haider and Tariq Alam

## ABSTRACT

Goldston syndrome is a rare entity describing the association of polycystic kidneys and Dandy Walker malformation with or without hepatic fibrosis. A 28 years old pregnant woman came to radiology department for the first antenatal scan. Ultrasound showed a single fetus corresponding to 27 week of gestation. The fetal brain revealed deficient vermis with a posterior fossa cyst communicating with the 4th ventricle suggestive of Dandy-Walker malformation (DWM). The kidneys were enlarged, and echogenic containing small cysts with associated amniotic fluid index of 5 cm suggestive of Oligohydramnios. A diagnosis of Goldston syndrome was suggested. These findings were confirmed on post natal head and renal ultrasound.

**Key words:** *Goldston syndrome. Dandy-Walker malformation. Hepatic fibrosis. Polycystic kidney. Antenatal screening.*

## INTRODUCTION

Dandy-Walker Malformation syndrome (DWM) is a rare disorder that is characterized by a triad of cerebellar vermis agenesis/dysgenesis with posterior fossa cyst communicating with the fourth ventricle and enlargement of the posterior fossa. DWM is frequently associated with neurological and systemic abnormalities of the cardiopulmonary, skeletal, genitourinary and gastrointestinal system that may not be lethal depending upon their severity. Goldston syndrome is an association of DWM with cystic dysplastic kidneys.<sup>1,2</sup>

It was first described by Goldston in 1963 and is a very rare disorder with few case reports further seen in the literature. Antenatally, only 2 diagnosed cases have been reported.<sup>3</sup> In the following report a case of Goldston syndrome diagnosed on antenatal ultrasound is presented.

## CASE REPORT

A 28 years old pregnant woman reported for the first time for routine antenatal scan at the radiology department of the Aga Khan University Hospital in Karachi in January 2009. The obstetric course of the present pregnancy had been uneventful till date. No history of previous congenital abnormalities had been reported in the family. Previous sibling was a single normal alive child of 3 years from a non-consanguineous marriage. Ultrasound scan revealed a single fetus with deficient midline vermis and anechoic cystic area in the posterior fossa. Communication of

anechoic cystic area was established with the 4th ventricle. There was no hydrocephalus. Rest of the intracranial structures was normal. The fetal abdomen had enlarged echogenic kidneys. The right kidney measured 5.8 cm in length and 4.2 cm in antero-posterior diameter and the left kidney measured 5.4 cm in length with anteroposterior diameter of 2 cm (Figure 1). Oligohydramnios was also noted. Rest of the ultrasound scan of abdominal viscera and spine was unremarkable.

The pregnancy was uneventful. Baby was delivered at 40 weeks of gestation with normal apgar scores. Postnatal ultrasound scan was obtained on the 4th day of life to evaluate the baby. Ultrasound of the brain confirmed the absence of vermis with posterior fossa cyst communicating with the 4th ventricle (Figure 2). There was also facial dysmorphism with low set ears and slanting eyes. However, no other midline facial defects were noted. The kidneys revealed echogenic parenchyma with tiny cysts scattered in the cortex (Figure 3). Laboratory findings included a raised creatinine of 1.6 mg/dl, and reduced levels of serum chloride 86 mmols/l (normal range = 104-114) and serum bicarbonate 5.7 mmols/l (normal range = 17.5-27.5).

The neonate's liver function test and thyroid stimulating hormone levels were normal. The tests were repeated after 3 days. The serum creatinine, chloride and bicarbonate all fell within normal limits. Fetal blood chromosome karyotyping revealed 46, XX (20). Postnatal course of the neonate was uneventful and the child was discharged, and parents were instructed to bring the baby to pediatrics clinic for regular follow-ups.

## DISCUSSION

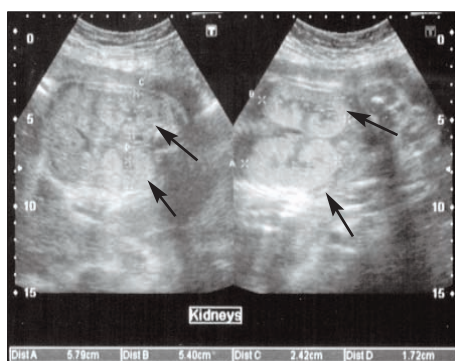The association of renal syndromes with CNS abnormalities is reported as a rare entity.<sup>2</sup> The first syndrome that had been described of this combination was the Meckel-Gruber syndrome, also described as the prototype syndrome and comprised of several serious

*Department of Radiology, The Aga Khan University Hospital, Karachi.*

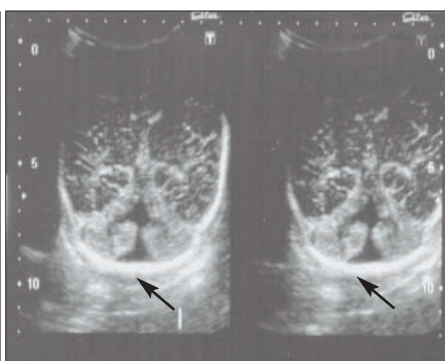
**Correspondence:** *Dr. Imrana Masroor, 36/1, 11th Commercial Street, Phase 4, DHA, Karachi.*

*E-mail: imrana.masroor@aku.edu*

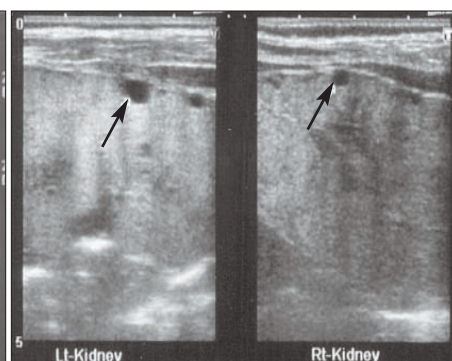
*Received February 1, 2010; accepted February 3, 2011.*



**Figure 1:** Antenatal ultrasound of a 32 weeks pregnant female. Axial (right) and coronal (left) view of fetal abdomen in lumbar area: bilateral enlarged echogenic .



**Figure 2:** Post natal head ultrasound coronal view showing the cerebellum and a posterior fossa cyst communicating with 4th ventricle secondary to absent vermis (black arrow).



**Figure 3:** Post natal ultrasound images longitudinal sections showing echogenic kidneys with multiple tiny cysts.

anomalies such as cerebral rachischisis and occipital meningoencephalocele, ocular anomalies, cleft palate, polydactyly, cardiac anomalies, cystic kidneys, pseudohermaphroditism and other malformations. However, this constitutes a spectrum of anomalies that are quite incompatible with life and on prenatal diagnosis termination of pregnancy is considered. Approximately 1/5th of patients with Meckel's syndrome have hepatic anomalies, primarily congenital hepatic fibrosis.<sup>2</sup> Another syndrome associated with DWM, congenital hepatic fibrosis and generalized cystic dysplastic renal lesions are characterized as Miranda syndrome or cerebrohepatorenal syndrome which is a rare familial disorder.<sup>4</sup> Goldston syndrome is combination of cystic dysplastic kidneys with DWM which were both present in this patient. Both Miranda and Goldston syndrome appear to be milder variants of Meckel's syndrome with fewer congenital anomalies.

The Goldston or cerebro-renal syndrome is a rare entity and the first case was reported by Goldston in 1963, who reported 3 siblings with diffuse cystic renal dysplasia but no hepatic fibrosis.<sup>5</sup> Two of the cases described by him also had DWM, and were similar to this case. Gloeb *et al.* reported a syndrome which also had spectrum of cerebro-renal abnormalities.<sup>3</sup> There was association of DWM with echogenic kidneys in a male infant born prematurely weighing 635 grams only. There was no hepatic fibrosis. This was the first report of an antenatal diagnosis of Goldston syndrome. The second case of antenatal diagnosis of Goldston syndrome was by Gulcan *et al.* who described a male born to parents in a non consanguineous marriage prematurely weighing 1270 grams.<sup>1</sup> Postnatal course was difficult due to premature lung disease grade 4 with the baby expiring on the 7th day of life. Chromosome analysis in utero showed a 46 XY karyotype.

Moerman *et al.* reported 2 siblings who were born with a combination of central nervous system malformation, renal dysplasia and hepatic ductal plate malformation. Out of them first sibling had DWM on basis of which a

diagnosis of Goldston syndrome was made. But both these patients had cranium bifidum with defects in squamous part of temporal bone. The question was raised as to whether Goldston was actually a separate entity or was a less severe variant of the reported Meckel-Gruber syndrome.<sup>6</sup>

The previous theory was refuted by Walpole *et al.* who described the case of 3 non-viable brothers who had DWM (variant) with enlarged dysplastic polycystic kidneys and hepatic fibrosis.<sup>7</sup> However, no encephalocele with polydactyly was reported. Walpole *et al.* suggested the possibility of a distinct and separate syndrome; the Goldston syndrome. This presentation is also similar to Miranda's syndrome. After this report it was suggested that the phenotypic spectrum of Meckel's syndrome includes those described as Goldston and Miranda's syndrome.

The most recent report of Goldston syndrome was received from India in which a 32 years old woman presented with bilateral subdural hematomas and chronic renal failure on abdominal ultrasound. Subsequent MRI of the brain revealed Dandy-Walker malformation with hypo-plastic vermis. This case was the first to be reported in an adult patient.<sup>8</sup>

The diagnoses of Dandy-Walker malformation and enlarged echogenic kidneys can be made on prenatal scans. Thus efforts to identify such syndromes which are incompatible with life should be meticulous and stringent. Furthermore chromosomal analysis and karyotyping should be conducted to further enlighten the scenario.

In conclusion, presence of DWM on antenatal scanning should necessitate a search for other associated extracranial malformations, particularly in genitourinary, cardiac, skeletal and gastrointestinal system.

## REFERENCES

1. Gulcan YH, Duman N, Kumral A, Sagol O, Lebe B, Kavukcu S, *et al.* Goldston syndrome: report of a case. *Genet Couns* 2001; **12**:263-7.

2. Bernstein J, Brough AJ, McAdams AJ. The renal lesion in syndromes of multiple congenital malformations. Cerebro-hepatorenal syndrome; Jeune asphyxiating thoracic dystrophy; tuberous sclerosis; Meckel syndrome. *Birth Defects Orig Artic Ser* 1974; **10**:35-43.
3. Gloeb DJ, Valdes-Dapena M, Salman FO, Sullivan MJ, Quetel TA. The Goldston syndrome: report of a case. *Pediatr Pathol* 1989; **9**:337-43.
4. Kudo M, Tamura K, Fuse Y. Cystic dysplastic kidneys associated with Dandy-Walker malformation and congenital hepatic fibrosis. Report of two cases. *Am J Clin Pathol* 1985; **84**:459-63.
5. Goldston AS, Burke EC, D'Agostino A, Maccaughey WT. Neonatal polycystic kidney with brain defect. *Am J Dis Child* 1963; **106**: 484-8.
6. Moerman P, Pauwels P, Vandenberghe K, Lauweryns JM, Fryns JP. Goldston syndrome reconsidered. *Genet Couns* 1993; **4**:97-102.
7. Walpole IR, Goldblatt J, Hockey A, Knowles S. Dandy-Walker malformation (variant), cystic dysplastic kidneys, and hepatic fibrosis: a distinct entity or Meckel syndrome? *Am J Med Genet* 1991; **39**:294-8.
8. Menon R, Nadkarni T, Desai K, Goel A. Dandy-Walker malformation associated with polycystic kidneys: Goldston syndrome revisited. *J Clin Neurosci* 2006; **13**:875-7. Epub 2006 Aug 23.

