



6-2016

Review of various intraoperative neurophysiologic monitoring techniques

Liaquat Ali

Hamad Medical cooperation (HMC) Doha, Qatar.

Ambreen Iqrar

Hamad Medical cooperation (HMC) Doha, Qatar.

Bhojo Asumal Khealani

Hamad Medical cooperation (HMC) Doha, Qatar

Follow this and additional works at: <http://ecommons.aku.edu/pjns>

 Part of the [Neurology Commons](#)

Recommended Citation

Ali, Liaquat; Iqrar, Ambreen; and Asumal Khealani, Bhojo (2016) "Review of various intraoperative neurophysiologic monitoring techniques," *Pakistan Journal of Neurological Sciences (PJNS)*: Vol. 11 : Iss. 2 , Article 10.

Available at: <http://ecommons.aku.edu/pjns/vol11/iss2/10>

REVIEW OF VARIOUS INTRAOPERATIVE NEUROPHYSIOLOGIC MONITORING TECHNIQUES

Dr Liaquat Ali¹ (ABCN, ABEM), Dr Ambreen Iqar² (FCPS), Dr Bhojo Asumal Khealani³(ABCN).

¹- Assistant Consultant Neurologist and Neurophysiologist (ABCN-IONM, ABEM), Neurology department, Hamad Medical cooperation (HMC) Doha, Qatar. lali5@hamad.qa

²- Assistant Consultant Neurologist and Neurophysiologist (FCPS), Neurology department, Hamad Medical cooperation (HMC) Doha, Qatar.

³- Consultant Neurologist and Neurophysiologist (FCPS, ABCN), Neurology department Aga Khan University Hospital Karachi, Pakistan. bohjo.khealani@aku.edu

Correspondence address: Ali; Neurology department, Hamad Medical cooperation (HMC) Doha, Qatar. lali5@hamad.qa
Date of submission: January 11, 2016 **Date of revision:** May 25, 2016 **Date of acceptance:** June 1, 2016

ABSTRACT

IONM is used to monitor nervous tissues (including brain, spinal cord, cranial nerves and peripheral nerves) in real-time during surgeries, alert neurological injuries and corrective measures and prevent disability. There are various IONM monitoring techniques including evoke potentials (SSEP, BAEP, MEP), EMG (Free-running and triggered), NAP (Nerve action potential) and Electroencephalography (EEG) to monitor the functional integrity of neural structures. SSEP evaluates integrity of posterior column-medial lemniscus pathway. SSEP is clinical use in spinal cord surgeries, vascular surgeries (carotid endarterectomy, cerebral aneurysm surgery etc), and localization of sensor motor cortex. BAEP evaluates integrity of peripheral and central auditory pathway. BAEP is clinical use in CP angle tumors surgery (acoustic neuroma, meningioma), microvascular decompression of CN-VII for hemifacial spasm, CN-V for trigeminal neuralgia, CN-IX for glossopharyngeal neuralgia, skull base surgery, Suboccipital decompression (e.g. fractures/dislocation C-1 vertebra, Chiari malformation). MEP evaluates integrity of motor pathway. MEP is sensitive to neuromuscular blocker anesthetic medications. Clinical utility of MEP including any surgery risking motor pathway injury include tumor near the motor cortex or corticospinal tract, intracranial aneurysm clipping, posterior fossa surgery, tethered cord or cauda equina surgeries, spinal deformity or fracture surgery, vertebral tumor resections, and anterior cervical discectomy, descending aortic procedures, spinal arteriovenous malformation interventions and carotid endarterectomy. EMG (free running and triggered) evaluates integrity of innervating nerves and electrical activity of muscles. Clinical utility of facial and other cranial nerve monitoring in posterior fossa surgery (eg, acoustic neuroma), selective dorsal rhizotomy, tethered cord release, Pedicle screw placement and Anal or urinary sphincter function monitoring.

INTRODUCTION

Intraoperative neurophysiologic monitoring (IONM) aims to assess ongoing functional integrity of the central or peripheral nervous system in the operating room (OR) or other acute care units^[1]. IONM is used to monitor nervous tissues in “real time” during surgery, and to alert surgeon to potential neurological injury and implement corrective measures to prevent permanent disability, thus improving safety and surgical outcomes. Intraoperative neurophysiologic monitoring is performed using a variety of neurophysiologic techniques including; Evoked potentials (EPs), Electromyography (EMG), Nerve action potential (NAP) and Electroencephalography (EEG) to monitor the functional integrity of certain neural structures including brain, spinal cord, cranial nerves and peripheral nerves^[2]. It is performed in a variety of surgical procedures including scoliosis surgery, spinal cord surgeries, epilepsy surgery, posterior fossa

surgeries including microvascular decompression, vascular surgeries including carotid endarterectomy and aortic aneurysm surgeries^[2].

History:-

Foerster and Altemberger were first to use IONM- EEG in 1935^[3]. Herbert Jasper and Wilder Penfield using electrocorticography (ECoG) for localization and surgical treatment of epilepsy in late 1930-1950^[3]. They also performed careful mapping of cortical function by direct electrical stimulation. In 1954, Amassian found that single-pulse Direct Cortical Stimulation (DCS) and recording from epidural space evokes several corticospinal tract volleys consisting of a bi- or triphasic sharp discharge, called a D (direct) wave, followed by polyphasic waves, called I (indirect) waves. The D wave results from direct stimulation of corticospinal neurons, whereas the I wave is generated by transsynaptic activation of

corticospinal neurons. Subsequently, Merton and Morton in 1980 and Barker et al. in 1987 described transcranial electric stimulation (TES) and transcranial magnetic stimulation (TMS) muscle MEPs. [5][6] In the early 1960s, intraoperative monitoring of the facial nerve was performed to reduce the risks of facial palsy after vestibular schwannoma surgery [7]. In the 1970s, intraoperative monitoring of spinal cord to reduced the risk of damage during scoliosis surgery using SEPs by Dr. Richard Brown [8]. Leonid Malis, who leader of the use of microneurosurgical techniques, used the recordings of evoked potentials from the sensory cortex [9]. In the early 1980s, microvascular decompression (MVD) surgery for hemifacial spasm (HFS) and trigeminal neuralgia pioneered by Betty Grundy and Peter Raudzens [10][11]. In the 1980s, IONM was introduced in surgeries for large skull base tumors monitoring many cranial nerves depending on the location of the tumor [12][13][14]. During the 1990s with the development of techniques using magnetic and electrical stimulation of the motor cortex and stimulation of the spinal cord [15][16][17].

Dr. Gaston Celesia, mapped the auditory cortex in humans and studied SEP from the thalamus and primary somatosensory cortex [18][19][20]. Fred Lenz has studied the responses from nerve cells in the thalamus in awake humans using microelectrodes and mapped the thalamus with regard to the involvement in painful stimulation as well as in response to innocuous somatosensory stimulation [21][22][23].

Various IONM modalities:-

(A) Evoked Potentials:-

(i) Somatosensory Evoked Potentials (SSEP)

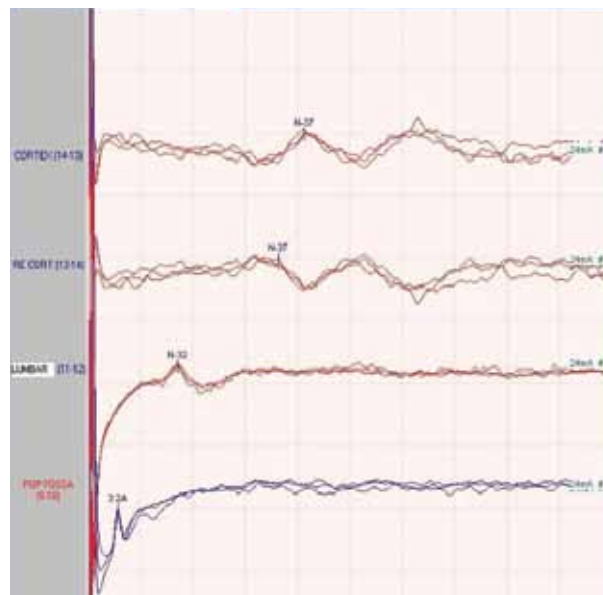
Technique:-

SSEP evaluates the integrity of the large fiber sensory system (Posterior column-medial lemniscus system). SSEPs are obtained by direct electrical stimulation of peripheral nerves (e.g. posterior tibialis at ankle, median, or ulnar nerves at the wrist) and recording at different levels within the neuraxis (e.g. brachial or lumbar plexus, cervical spine, parietal somatosensory cortex) of the far- and near-field potentials generated by the transmitted electrical volley. By assessing the electrical transmission through the large fiber sensory system, SSEPs have also an important role in monitoring its integrity or mapping its location, during a variety of surgeries that could result in its damage.

Parameters and interpretation:-

Amplitude and latencies of the responses are

monitored. Serially recorded responses are compared with laboratory norms. Establishing a reproducible baseline recording prior to any positioning or surgical manipulations is important. Changes from the baseline responses are the most important indicators of neurological dysfunction. Baseline values may need to be reestablished if changes in anesthetic medications or other physiological parameters occur during the case.



Normal post tibial nerve SSEP

Warning Criteria:-

For SSEPs, there are two general approaches to interpreting intraoperative changes.

- 1) Use predefined limits (commonly a 50% decrease in amplitude or 10% increase in latency).
- 2) Changes in waveform amplitude, latency, and morphology that exceed baseline variability, even in these changes are small or represent a change from prior consistent values [24].

Clinical utility

1) Spinal surgery:

Changes in latency and amplitude can be monitored during positional manipulations, including open or closed reduction of spinal deformities. Extradural, intradural and intramedullary lesions can be monitored.

2) Cranial/vascular surgery:-

- i) Carotid surgery including Endarterectomy: Changes

in SSEP recordings are sensitive for detection of cerebral ischemia and helpful in determining the need for shunting during the surgical procedure.

- ii) Cerebral aneurysm surgery: Changes may indicate occlusion of parent vessel branches, which potentially could be reversed by repositioning of aneurysm clips. SSEP monitoring can signal changes prior to irreversible cerebral ischemia. [25]
- iii) Aortic cross-clamping: Changes in SSEP indicate a high risk of neurological injury, especially if the changes are immediate.

3) Localization of sensorimotor cortex:

Localization of the motor cortex is important to minimize the risk of contralateral motor deficits resulting from surgical procedures in its surrounding area. When recording SSEP, the primary sensory cortex and motor cortex generate potentials that are mirror images of each other. This "phase reversal" across the central sulcus is a highly reproducible characteristic that can aid in the localization of primary motor cortex. Unfortunately, motor pathways may be injured while sparing sensory pathways by SSEP. The lack of direct anterior cord monitoring with SEP is difficult and cases of isolated anterior cord injury with preserved SEP spinal cord monitoring have occurred.

- (ii) Brainstem Auditory Evoked Potentials (BAEP) BAEPs are short-latency potentials reflecting the depolarization of several structures within the auditory pathways, because they are traversed by electrical volley triggered by the peripheral stimulation of the cochlear nerve. These evoked responses are far-field potentials, being recorded by electrodes placed on the scalp, with the exception of wave I, which is a near-field potential.

By assessing the amplitudes and latencies of these evoked responses, one can thus analyze the functional integrity of the corresponding anatomic structures. By recording the electrical transmission within the lower parts of the auditory pathways, from the cochlea to the upper pons, BAEPs are a good tool in assessing the integrity not only of the eighth nerve, but also of the brainstem structures involved in hearing, thus indirectly of the brainstem itself (as the name suggests).

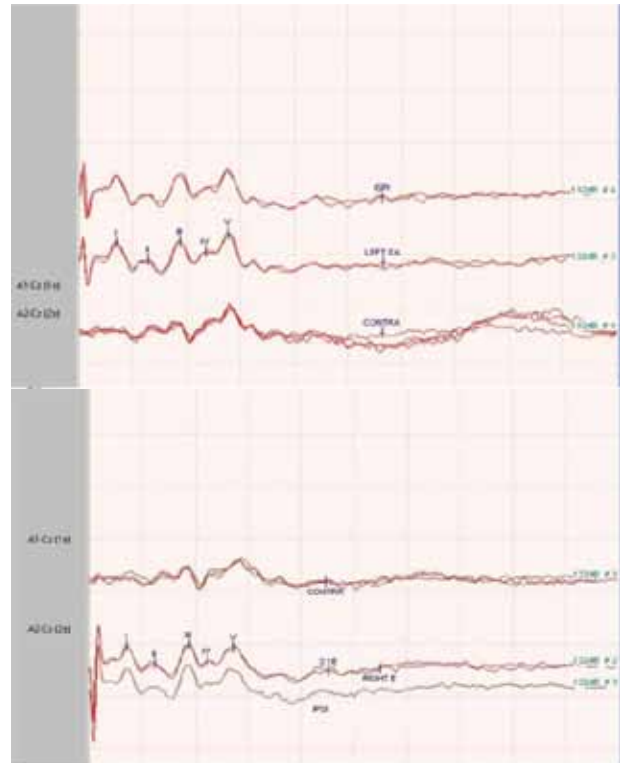


Figure: Schematic representation of the auditory pathways. Notice the neurophysiologic-neuroanatomical correlation between BAEPs and different levels within the auditory pathway.

Name Wave	Anatomical location (probable)
I (P1)	Distal acoustic nerve (Action potential)
II (P2)	Proximal acoustic nerve / Cochlear nucleus
III (P3)	Lower pons
IV (P4)	Mid/upper pons
V (P5)	Lower midbrain

Anatomical localization of BAEP Waves

Technique:-

Recordings are obtained by stimulating with auditory clicks in the ear. Click intensity of 100 dB pe SPL or 60-70 dB HL is commonly utilized. Standard EEG cortical montage is used with recordings obtained from scalp electrodes. Best responses are obtained from electrodes near the ears (A1, A2) referenced to the vertex (Cz)^[26].

Parameters and interpretation:-

Positive deflections are termed wave -I to wave-VII. Waves I, III, and V are the waves most consistently seen in healthy subjects (obligate waves). Wave V is the most reliably seen wave, particularly in patients with hearing impairment or undergoing surgery. Measurements of absolute latencies and amplitudes of waves I and V and I-V interpeak latency should be made on baseline recordings. It is essential that these baseline BAEPs be recorded using the same parameters for stimulation and recording that are to be used for intraoperative monitoring. Complete measurements of the all the various waves and their interpeak latencies are time consuming during intraoperative monitoring. However, continuous monitoring of the absolute latency and amplitude of wave V should be carried out. Significant changes in the wave V latency should be reported to the surgeon. Interpretation of intraoperative BAEPs is performed by comparing each sequential average to the baseline obtained at the start of the surgery. Each patient serves as his or her control.

Warning Criteria:-

Typical criteria of BAEP change used for alerting the surgeon are a 1 ms latency prolongation or a 50% drop in amplitude of the wave V. This criterion is somewhat arbitrary. [26]

Clinical utility:-

1) CN-VIII: - Changes in latency, interlatencies difference and amplitude of BEAP waves I, III and V can be monitored during CPA tumors surgery (e.g. acoustic neuroma, meningioma), microvascular decompression (MVD) of seventh nerve for hemifacial spasm, fifth nerve for trigeminal neuralgia and Ninth nerve for glossopharyngeal neuralgia.

2) Brainstem: - Changes in latency, interlatencies difference and amplitude of BEAP waves I, III and V can be monitored during CPA tumors, Skull base surgery, Suboccipital decompression (e.g. fractures/dislocation C-1 vertebra, Chiari malformation) and Vascular surgeries of posterior circulation.

Limitations:-

1) The stimulus used for BAEP is click which is broad band sound (500-4000 Hz) delivering a wide range

of audio frequencies so BAEP cannot exclude specific frequency hearing deficit or mild hearing deficit (<500Hz).

2) BAEP can change dramatically in neonates and infants before the age of two years. There is variation in latency and amplitudes values as age progresses before of 2 years.

3) Physiologic changes include decreased body temperature, cold water irrigation and decreased blood pressure can cause latency prolongation and amplitude decrement of the BAEP.

4) Technical problem can occur due to problems with the recording or stimulating electrodes, kinking of tubing delivering acoustic stimuli, equipment malfunction, or operator error.

(iii) Motor Evoked Potentials:-

Somatosensory evoked potential (SSEP) monitoring was used in the past to reduce the risk of motor system injury. [27] However, significant motor deficits have been seen in patients undergoing spinal surgery despite normal SSEPs. [27][28] This was inevitable because the two systems have distinct anatomy and vascular supply so that smaller lesions can damage only one or the other. Thus, the rationale for MEP monitoring is to directly test the motor system during surgery. In conjunction with SEPs, the anterior and posterior portions of the spinal cord can be monitored together. MEPs are sensitive to anesthetics and, especially, neuromuscular blockade.

Technique:-

MEPs are elicited by either electrical or magnetic stimulation of the motor cortex or the spinal cord. Recordings are obtained either as neurogenic potential in the distal spinal cord or peripheral nerve, or as myogenic potentials from the innervated muscle. Transcranial electrical stimulation involves stimulation of electrodes on the scalp, or if the brain is exposed by a craniotomy, stimulation of electrodes placed directly on the brain surface. [29]

Transcranial electrical motor evoked potentials (TceMEP) have been used more frequently in spinal surgery. Motor evoked potentials (MEPs) are obtained by electrically stimulating the brain and recording the response over the spinal cord (Direct = D and Indirect = I waves), peripheral nerves (nerve action potentials), or muscles (compound muscle action potentials, CMAP). Usually, recordings are made from small hand and foot muscles. Spinal

recordings (for D and I waves) are seldom used owing to the invasive methods required for recording. When recording MEPs from muscles, a train of high voltage (200 to 1000 V) stimuli is applied to the scalp to peripherally produce a CMAP. Large series have demonstrated the safe use of MEPs, and they are a useful adjunct to SEP monitoring. Using both modalities (MEP and SSEP), both the anterior and posterior aspects of the spinal cord can be monitored. Inhalational anesthetics suppress the anterior horn cells, and consequently their use makes obtaining MEPs more difficult. Intravenous anesthetics (propofol and opioids TIVA) are preferred when MEP monitoring is to be used.

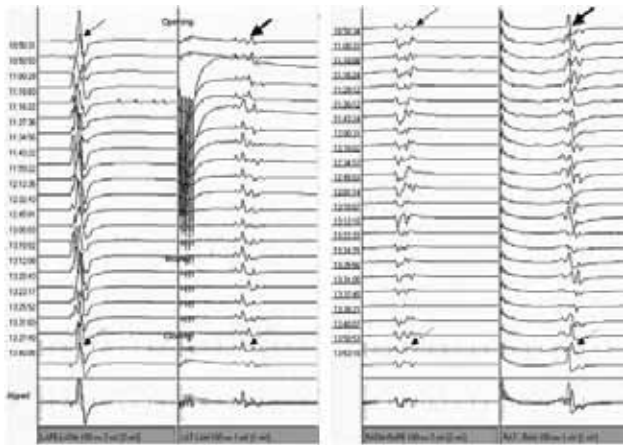


Figure: Intraoperative MEP monitors showing stable responses in the upper and lower extremities during a biopsy of a cervical lesion.

Parameters and interpretation:-

For robust MEP signals, complete loss of MEP signal or abrupt significant decrease in amplitude of 80% or more in the absence of an explanation other than surgical injury. Gradual changes in MEP signals more commonly reflect systemic factors or an “anesthetic fade” phenomenon, so gradual changes might be given less weight unless the onset of the change can be related to a surgical event that may result in gradual dysfunction [30].

Warning Criteria:-

Warning criteria for D-waves:-

1. Intramedullary spinal cord tumor surgery: - >50% amplitude reduction
2. Brain surgery with DCS cervical D-waves: - >30–40% amplitude reduction. [31]

Warning criteria for muscle MEPs:-

1. Spinal cord: - Disappearance is always a major criterion
 - i) For IMSCT surgery: - marked amplitude reduction, acute threshold elevation or morphology simplification could be additional minor criteria.
 - ii) For orthopedic spine surgery: - marked amplitude reduction or acute threshold elevation could be additional moderate criteria
 - iii) For descending aortic surgery: - marked amplitude reduction could be an additional moderate criterion
2. Brain and brainstem: - Major criteria include disappearance or consistent >50% amplitude reduction when warranted by sufficient response stability. Acute threshold elevation might be relevant
3. Facial nerve: - Major criteria include disappearance or consistent >50% amplitude reduction when warranted by sufficient response stability. [31]

Clinical utility:-

Indications for MEP monitoring include any surgery risking motor system injury. The most common indications arise during neurosurgical, orthopedic and vascular interventions. Neurosurgical indications include tumor or epileptic focus resections near the motor cortex or corticospinal tract, intracranial aneurysm clipping, posterior fossa surgery, craniocervical junction and spinal operations, spinal cord procedures and tethered cord or cauda equina surgeries. Orthopedic indications include spinal deformity or fracture surgery, vertebral tumor resections, and anterior cervical discectomy. Vascular indications include descending aortic procedures, spinal arteriovenous malformation interventions and carotid endarterectomy.

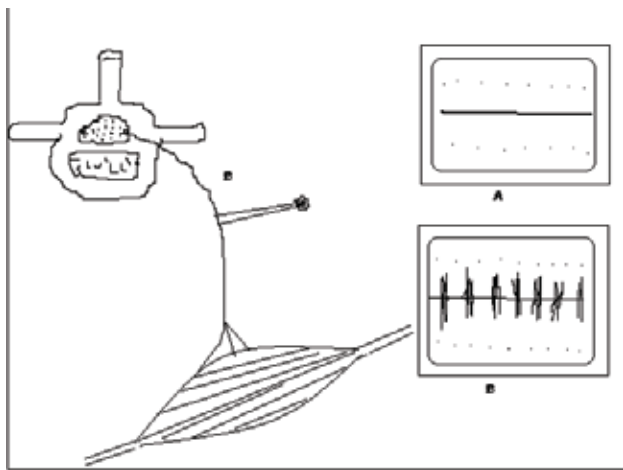
Safety and complications:-

Intraoperative MEP monitoring is sufficiently safe for clinical use in expert hands using appropriate precautions, but could involuntarily cause harm. Safety issues include hazardous output (excitotoxic, electrochemical or thermal injury of the brain or scalp), bite injuries, seizures, invasive electrode complications, movement-induced injury, arrhythmia, and relative contraindications include epilepsy; cortical lesions; skull defects; intracranial vascular clips, shunts, or electrodes; and pacemakers or other implanted bioelectric devices.

(B) Electromyography (EMG):-

(i) Free-running and Triggered EMG (f-EMG AND CMAPs):-

EMG is the recording of electrical activity of muscle. Changes in EMG recordings are indirect indicators of function of the innervating nerve. Intraoperative uses have stressed localization and assurance of the integrity of peripheral nerves, including cranial nerves. Free-run EMG (f-EMG) consists of recording spontaneous muscle activity, thus allowing its real-time assessment. In IONM we use this technique as a monitoring tool for detecting surgically driven mechanical irritation of the peripheral nervous system and of the cranial nerves, hopefully before irreversible damage to these structures had occurred. Triggered EMG consists of applying an electrical stimulus, directly on the peripheral motor nerves or roots, for eliciting CMAPs to be recorded in the corresponding muscle channels. Thus, it can be used as a mapping tool for detecting the location of peripheral or cranial nerves that may be difficult to distinguish from tumor, fibrous, and fatty tissues. Triggered EMG can also be used in checking the functions of injured (or that are at risk for injury) nerves, roots, or trunks by assessing the electrical transmission through such structures and comparing it with a healthy (or presurgical) baseline.



Free-running EMG activity for nerve root monitoring. A. EMG monitoring should be quiescent under normal conditions. B. Blunt mechanical nerve root irritation activates the motor nerve fibers, is transmitted down the nerve and across the neuromuscular junction, and evokes recordable motor unit potentials in the monitored muscle

Technique:-

Multiple EMG needles typically are placed into the muscles to be examined. Practically any muscle can be monitored, including face, tongue, and sphincter musculature. EMG is recorded continually with a low noise amplifier. Recordings are displayed visually and usually also sent to a speaker to provide auditory feedback. Changes in muscle electrical activity then can be seen and heard. When a peripheral nerve is to be localized intraoperatively, a sterile stimulating probe is used during the operation.

Interpretation:-

Free-running and Triggered EMG activity is monitored. Additionally, direct electrical stimulation of the nerve can help localize the neural structure. Note that Free-running EMG activity does not assure the integrity of the peripheral nerve. If Triggered EMG activity can be elicited consistently, integrity of the distal nerve and muscle can be assured.

Clinical Uses:-

Facial nerve/other cranial nerve monitoring:-

Cranial nerve monitoring is useful for surgical procedures in which the facial nerve is at risk, including posterior fossa surgery (eg, acoustic neuroma), vestibular neurectomy, surgery in the temporal bone, and parotid gland surgery.[32] Trigeminal, glossopharyngeal, vagus, spinal accessory, and hypoglossal nerve functions can be monitored similarly by EMG. Electrical stimulation in the operative field can evaluate the integrity of peripheral nerves. Spontaneous EMG activity suggests manipulation in the vicinity of the cranial nerve.

Selective dorsal rhizotomy:-

Selective dorsal rhizotomy (SDR) is a procedure that is used to reduce debilitating spasticity in conditions such as cerebral palsy by selectively transecting spinal rootlets. Overactive excitatory influence on motor nerves is believed to be reduced by removing facilitatory afferent input from muscle spindles. The procedure consists of stimulating spinal rootlets and monitoring EMG and motor function. Those rootlets that are associated with an abnormal motor response are sectioned selectively.

Tethered spinal cord release:-

Patients who undergo a tethered cord release procedure require dissection of scar tissue and possibly section of the filum terminale.

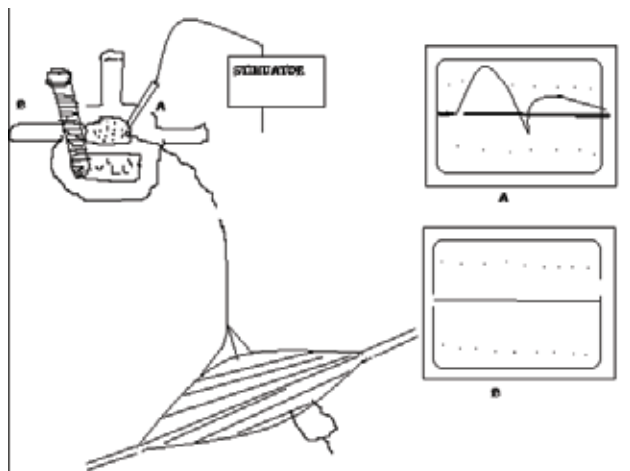
Distinguishing functional neural elements from nonfunctioning tissue is important. Stimulation of the roots of normally functioning nerves in the cauda equina elicits EMG activity. Monitoring lower extremity musculature, as well as anal and urethral sphincters, is important if the sacral roots are involved.

Pedicle screw placement:-

Use of pedicle screws as a fixation device in posterior spinal instrumentation in the lumbar region has become increasingly common. Various techniques to assure correct placement of the screws are advocated currently. EMG monitoring makes use of the fact that improperly placed screws that breach the cortical confines of the bony pedicle or vertebral body cause low impedance between the screw and the exiting nerve root underneath the pedicle. Properly placed screws that remain entirely within the bone have high impedance. If the screw is stimulated with constant current greater than 10 mA for pedicle screw without EMG activation, the screw is unlikely to have perforated the vertebral cortex. However, a response to stimulation at less than <7mA for pedicle screw suggests a bony defect that provides a low impedance pathway to the nerve root. [33]

	Perforation probable	Perforation Possible	Perforation Unlikely
Pedicle Screw	<7 mA	7-10mA	>10mA
Hole	<5mA	5-7Ma	>7mA

Threshold Values Indicating the Likelihood of Pedicle Screw Malpositioning



Stimulus-triggered EMG for detecting pedicular wall breach. A monopolar stimulator is inserted into a pedicle hole or touched against a pedicle screw. A. Holes or screws that have perforated the bony pedicle wall will lie directly against adjacent nerve roots and stimulation activates the adjacent nerve root, evoking a CMAP response. B. Holes or screws that are correctly positioned within the pedicle wall are separated from the adjacent nerve roots by a cortical bony layer, with high impedance to the passage of electrical current and no evoked CMAP responses.

Sphincter Function Monitoring:-

Anal or urinary sphincter dysfunction is a devastating complication of cauda equina surgery. By monitoring sphincter function, the risk of this complication can be reduced. The anal and external urethral sphincters and Detrusor muscle can be monitored. Anal sphincter monitoring is the easiest and is performed most commonly. Monopolar subdermal needle electrodes (similar to those used to perform EMG monitoring) are inserted percutaneously in the anal sphincter muscle after the patient has been anesthetized. These electrodes can record free-running EMG activity, including neurotonic discharges and triggered EMGs. The external urethral sphincter surrounds the proximal part of the urethra and is not accessible percutaneously. Consequently needle electrodes cannot be inserted into this sphincter. To monitor the external urethral sphincter, a specially made ring electrode is attached to a Foley catheter 1 to 2 cm distal to the bulb. This ring electrode serves as a bipolar surface electrode that records stimulated and free-running EMGs. The detrusor muscle can be monitored. Changes in bladder pressure are used as surrogate markers for muscle integrity. Prior to surgery, a cystometrogram is performed to determine the capacity of the bladder. At the time of surgery, a Foley catheter is inserted and attached to a three-way flow adapter, which is attached to a manometer. The bladder is filled with fluid to capacity. Contraction of the detrusor muscle causes an increase in bladder pressure, which is measured by the manometer. Additionally, during surgery, sustained high frequency stimulation in the operative field is needed to induce detrusor muscle contraction. When the contraction occurs, it is delayed for several seconds. This results in a delay in providing feedback to the surgeon. [34][35]

Combination of tests: Applications in IONM

Surgical procedure	Combination of tests
Cervical and low thoracic/lumbar surgeries (e.g. decompressive surgery for trauma, spondylosis, extradural tumors, tethered cord, intraduralextramedullary tumors such as schwannomas, etc.)	i) SSEPs/MEPs. ii) Free and triggered EMG.
Brainstem surgery (e.g. suboccipital decompression: Chiari malformation, tumor resection, vascular surgery of the posterior fossa)	i) SSEPs/MEPs. ii) Cranial nerve monitoring (CN IX, X, XI, and XII for medulla; V, VII, and VIII for pons; III, IV, and VI for midbrain).
CPA tumors, microvascular decompressions (MVD) of CN V and CN VII	i) BAEP. ii) Monitoring of CN V and VII.
Functional cortical mapping	i) Median SSEPs for central sulcus localization via phase reversal technique. ii) MEPs triggered by direct electrical cortical stimulation for motor mapping. iii) ECoG for appreciating the baseline cortical excitability prior to stimulation and for monitoring of after-discharge.
Epilepsy surgery	i) ECoG for mapping of the irritative zones. ii) Functional cortical mapping.
Peripheral nervous system surgery (e.g. brachial plexus exploration, nerve repair)	i) SSEPs to rule out root avulsion, ii) MEPs. iii) Nerve-to-nerve recording (NAP). iv) nerve-to-muscle recording (triggered CMAPs).
Aortic aneurysm repair	i) SSEPs/MEPs. ii) EEG to monitor for cerebral ischemia.

References

1. <http://www.asnm.org>.
2. Husain AM, editor. ed. A Practical Approach to Neurophysiologic Intraoperative Monitoring. New York: Demos; 2008
3. Penfield W, Jasper H. Epilepsy and the Functional Anatomy of the Human Brain. 1954.
4. Patton HD, Amassian VE. Single and multiple unit analysis of cortical stage of pyramidal tract

- activation. *J Neurophysiol* 1954; 17:345–63.
5. Merton PA, Morton HB. Stimulation of the cerebral cortex in the intact human subject. *Nature* 1980;285:287
 6. Barker AT, Freeston IL, Jalinous R, Jarratt JA. Magnetic stimulation of the human brain and peripheral nervous system: an introduction and the results of an initial clinical evaluation. *Neurosurgery* 1987; 20:100–9.
 7. Hilger J (1964) Facial nerve stimulator. *Trans Am Acad Ophthalmol Otolaryngol* 68:74–6.
 8. Brown RH and CL Nash (1979) Current status of spinal cord monitoring. *Spine* 4:466–78.
 9. Malis LI (1995) Intra-operative monitoring is not essential. *Clin Neurosurg* 42:203–13.
 10. Grundy B (1983) Intraoperative monitoring of sensory evoked potentials. *Anesthesiology* 58:72–87.
 11. Raudzens PA (1982) Intraoperative monitoring of evoked potentials. *Ann N Y Acad Sci* 388:308–26.
 12. Møller AR (1987) Electrophysiological monitoring of cranial nerves in operations in the skull base, in *Tumors of the Cranial Base: Diagnosis and Treatment*, LN Sekhar and VL Schramm Jr, Editors. Futura Publishing Co: Mt. Kisco, New York. 123–32.
 13. Sekhar LN and AR Møller (1986) Operative management of tumors involving the cavernous sinus. *J Neurosurg* 64:879–89.
 14. Yingling C and J Gardi (1992) Intraoperative monitoring of facial and cochlear nerves during acoustic neuroma surgery. *Otolaryngol Clin North Am* 25:413–48.
 15. Barker AT, R Jalinous and IL Freeston (1985) Non-invasive magnetic stimulation of the human motor cortex. *Lancet* 1:1106–7.
 16. Marsden CD, PA Merton and HB Morton (1983) Direct electrical stimulation of corticospinal pathways through the intact scalp in human subjects. *Adv Neurol* 39:387–91.
 17. Deletis V (1993) Intraoperative monitoring of the functional integrity of the motor pathways, in *Advances in Neurology: Electrical and Magnetic Stimulation of the Brain*, O Devinsky, A Beric and M Dogali, Editors. Raven Press: New York. 201–14.
 18. Celesia GG, RJ Broughton, T Rasmussen et al (1968) Auditory evoked responses from the exposed human cortex. *Electroencephalogr Clin Neurophysiol* 24:458–66.
 19. Celesia GG and F Puletti (1969) Auditory cortical areas of man. *Neurology* 19:211–20.
 20. Celesia GG (1979) Somatosensory evoked potentials recorded directly from human thalamus and Sm I cortical area. *Archives of Neurology* 36:399–405.
 21. Greenspan JD, RR Lee and FA Lenz (1999) Pain sensitivity alterations as a function of lesion localization in the parasyllian cortex. *Pain* 81:273–82.
 22. Lenz FA and PM Dougherty (1995) Pain processing in the ventrocaudal nucleus of the human thalamus, in *Pain and the Brain*, B Bromm and JE Desmedt, Editors. Raven Press: New York. 175–85.
 23. Lenz FA, JI Lee, IM Garonzik et al (2000) Plasticity of pain-related neuronal activity in the human thalamus. *Prog Brain Res* 129:253–73.
 24. <http://www.acns.org>; Guideline 11A: Recommended standards for Neurophysiologic intraoperative monitoring-Principles.2009
 25. Goryawala M, Yaylali I, Cabrerizo M, Vedala K, Adjouadi M. An effective intra-operative neurophysiological monitoring scheme for aneurysm clipping and spinal fusion surgeries. *J Neural Eng. Apr* 2012; 9(2):026021. [Medline].
 26. <http://www.acns.org>; Guideline 11 C: Recommended standards for intraoperative Auditory Evoked Potentials.2009.
 27. Nuwer MR, Dawson EG, Carlson LG, Kanim LE, Sherman JE. Somatosensory evoked potential spinal cord monitoring reduces neurologic deficits after scoliosis surgery: results of a large multicenter survey. *Electroencephalogr Clin Neurophysiol* 1995; 96:6–11.
 28. Lesser RP, Raudzens P, Luders H, Nuwer MR, Goldie WD, Morris 3rd HH, et al. Postoperative neurological deficits may occur despite unchanged intraoperative somatosensory evoked potentials. *Ann Neurol* 1986; 19:22–5.
 29. Li F, Gorji R, Allott G, Modes K, Lunn R, Yang ZJ. The usefulness of intraoperative neurophysiological monitoring in cervical spine surgery: a retrospective analysis of 200 consecutive patients. *J Neurosurg Anesthesiol. Jul* 2012; 24(3):185-90. [Medline].
 30. Lyon R, Feiner J, Lieberman JA. Progressive suppression of motor evoked potentials during general anesthesia: the phenomenon of “anesthetic fade”. *J Neurosurg Anesthesiol* 2005; 17:13–19.
 31. MacDonald DB, Skinner S, Shils J, Yingling C. Intraoperative motor evoked potential monitoring – A position statement by the American Society of Neurophysiological Monitoring. *Clin Neurophysiol* (2013), <http://dx.doi.org/10.1016/j.clinph.2013.07.025>.

32. Kircher ML, Kartush JM. Pitfalls in intraoperative nerve monitoring during vestibular schwannoma surgery. *Neurosurg Focus*. Sep 2012; 33(3):E5.
33. Calancie B, Madsen P, Lebowitz N. Stimulus evoked EMG monitoring during transpedicular lumbosacral spine instrumentation. Initial clinical results. *Spine* 1994; 19:2780–2786.
34. Krassioukov AV, Sarjeant R, Arkia H, Fehlings MG. Multimodality intraoperative monitoring during complex lumbosacral procedures: indications, techniques, and long-term follow-up review of 61 consecutive cases. *J Neurosurg Spine* 2004; 1:243–253.
35. Shinomiya K, Fuchioka M, Matsuoka T, et al. Intraoperative monitoring for tethered spinal cord syndrome. *Spine* 1991; 16:1290–1294.

Conflict of interest: Author declares no conflict of interest.

Funding disclosure: Nil

Author's contribution:

Liaquat Ali: Study concept and design, protocol writing, data collection, data analysis, manuscript writing, manuscript review

Ambreen Iqrar: data collection, data analysis, manuscript writing, manuscript review

Bhojo Khealani: Study concept and design, data analysis, manuscript writing, manuscript review