



6-2016

Surgical outcome of benign intracranial hypertension in terms of improvement in vision

Naeem ul haq

Gajju Khan Medical College, Bacha Khan Medical Complex, Swabi - Pakistan., brainsurgeon1978@yahoo.com

Naseer hassan

Gajju Khan Medical College, Bacha Khan Medical Complex, Swabi - Pakistan.

Muhammad ishaq

Gajju Khan Medical College, Bacha Khan Medical Complex, Swabi - Pakistan.

Muhammad usman

Gajju Khan Medical College, Bacha Khan Medical Complex, Swabi - Pakistan.

Follow this and additional works at: <http://ecommons.aku.edu/pjns>



Part of the [Neurology Commons](#)

Recommended Citation

ul haq, Naeem; hassan, Naseer; ishaq, Muhammad; and usman, Muhammad (2016) "Surgical outcome of benign intracranial hypertension in terms of improvement in vision," *Pakistan Journal of Neurological Sciences (PJNS)*: Vol. 11 : Iss. 2 , Article 6.
Available at: <http://ecommons.aku.edu/pjns/vol11/iss2/6>

SURGICAL OUTCOME OF BENIGN INTRACRANIAL HYPERTENSION IN TERMS OF IMPROVEMENT IN VISION

Naeem ul haq¹, Naseer hassan¹, Muhammad ishaq¹, Muhammad usman²

¹Neurosurgery unit , Lady reading hospital Peshawar

²Neurosurgery Unit, Gajju Khan Medical College, Bacha Khan Medical Complex, Swabi - Pakistan.

Correspondence address: Dr.Naeem ul haq : Brainsurgeon1978@yahoo.com

Date of submission: December 22, 2015 **Date of revision:** May 17, 2016 **Date of acceptance:** May 30, 2016

ABSTRACT

OBJECTIVE; To know about surgical outcome of benign intracranial hypertension in terms of improvement of vision. **METHODOLOGY ;** This Prospective observational study was conducted at of 22 patients operated in neurosurgery unit lady reading hospital Peshawar from Jan 2011 to Jun 2014. Written consent was obtained from all the patients or their relatives All patients of either age and sex with Diagnosed cases of BIH were included in the study, Patients with depressed conscious level, malignant hypertension, space occupying lesion in brain on MRI and those Patients unfit or unwilling for surgery were excluded from the study. Patients particulars like age ,gender , and post operative outcome was documented on predesigned proforma . All the results were analyzed by spss version 16 and represented in the form o graphs/charts and tables. **RESULTS;-** Total 22 patients of BIH were studied which were all females (100%) having age range of 18 to 58 years with mean of 38 ± 5 years SD. Headache was present in all (100%) patients followed by visual deterioration having 20(90.90%) cases. CSF manometry showed opening pressure from 28cm of H₂O to 50 cm of H₂O, with mean of 39. 19. Post operatively headache improved in 16(72%) patients, Papilledema in 18(81.81%) caseswhile 4(18%) patients did not improved. In 2(9.09%) cases there was and CSF leak was in 1(4.54%) case. **CONCLUSION;** BIH has good surgical outcome in terms of improvement in vision, if managed before advanced stage of Papilledema

KEYWORDS: Surgical outcome, Benign intracranial hypertension, Visual improvement

INTRODUCTION

Benign intracranial hypertension (BIH) or pseudotumourcerebri is defined as a syndrome of signs and symptoms of increased intracranial pressure without clinical, laboratory or radiologic evidence of causative lesions on magnetic resonance imaging (MRI) or computed tomography¹. BIH occurs most commonly in obese women of reproductive age. The incidence is approximately 1/100 000/year rising to 13/100 000/ year in women who are 10% above ideal body weight between 20 and 44 years. BIH less frequently seen in males and children. Prevalence rates are higher, showing the chronic nature of the condition in majority cases^{2,3,4,5}. Average age at the time of diagnosis Benign intracranial Hypertension is 30 years⁶. Some medications such as steroid withdrawal, lithium, tetracycline's, and vitamin analogs and systemic conditions such as obstructive sleep apnea, renal failure, coagulopathies, and anemia have also been associated with BIH^{6,7,8}. Cerebral venous hypertension due to Dural venous sinus thrombosis, neoplastic obstruction of siuses or a duralarteriovenous

malformation causes a very similar clinical picture and diagnosis of BIH is made when cerebral venous obstruction and other causes of raised intracranial pressure have been ruled out on Neuroimaging⁹. The symptoms of BIH patients are headache (94%), transient visual obscurations (68%), pulse-synchronous tinnitus (58%), photopsia (54%), and retrobulbar pain (44%). Diplopia (38%) and visual loss (30%) are less commonly features of BIH¹⁰. To diagnose BIH we should have (1) Raised intracranial pressure; (2) Normal neurologic examination except Papilledema and an occasionally abducens nerve palsy (3) the absence of a space-occupying lesion, or ventricular enlargement on computed tomography or magnetic resonance imaging; and (4) a normal cerebrospinal fluid composition^{10,11,12}. In addition to these features CSF manometry is of diagnostic and therapeutic importance. CSF opening pressure greater than 250 mm H₂O is diagnostic, less than 200 mm H₂O is normal, and 201 to 249 mm H₂O is nondiagnostic¹³. Management aim is controlling symptoms of raised intracranial pressure (ICP) and prevention of loss of vision due to Papilledema. Dietary

modification and weight loss are time part of initial management^{14,15} , Repeated lumbar puncture are sometimes used in patients to control symptom , in pregnant women, or in the setting of rapidly declining vision to temporarily lower¹⁶ and optimize the CSF pressure. Acetazolamide a carbonic anhydrase inhibitor is used for lowering the intracranial hypertension by decreasing CSF production (Doses of 1 to 2 g).Surgical treatment is indicated in cases with failed medical treatment or rapidly deteriorating vision. Generally, the indication for a CSF diversion procedure is failed medical treatment or intractable headache¹⁷. There are many surgical treatment options like lumboperitoneal shunt^{18,19,20} optic nerve sheath fenestration^{21,22}, ventriculoperitoneal (VP) shunt^{23,24,25}and venous sinus stenting for patients of BIH^{26,27} . Currently Lumboperitoneal shunt is most commonly advised to patients of BIH. As vision deterioration and headache are the most common presenting and disabling feature of patients with BIH, therefore we conducted this study to determine outcome of lumboperitoneal shunt in patients with BIH in terms of improvement in vision..

Material and methods

We conducted this Prospective observational study of 22 patients operated in neurosurgery unit lady reading hospital Peshawar from Jan 2011 to Jun2014. Written consent was obtained from all the patients or their relatives All patients of either age and sex with Diagnosed cases of BIH were included in the study, Patients with depressed conscious level, Malignant hypertension, Patients with space occupying lesion in brain on MRI, Patients unfit for surgery and unwilling for surgery were excluded from the study.Pre operative fundus examination and visual field charting was done in all the cases. Pre-operatively CT scan /MRI brain was done in all the patients. MR venography was also done in all patients. Cerebrospinal fluid examination was performed in all patients. All patients were admitted through OPD in ward. Preoperative work up was done in all cases. Hematologic tests like FBC,Urea,RBS, and Serologic tests like HBS and HCV were done for all cases. Lumboperitoneal shunt was done in all cases under G.A.

TECHNIQUE OF SURGERY

Position;Lateral decubitus position with both knee flexed.

Skin incision:

1.5 to 2 cm at L3-L4 or L4-L5 level extended down to the lumbar fascia overlying the spinous processes. Tilt table to 30 degree Reverse Trendelenburg to Increase lumbar subarachnoid space. Then Insertion of 14-gauge Tuohy needle in interspinous space to reach into the subarachnoid space, with opening directed rostrally. Removal of the trocar with insertion of shunt tube (8 to 10 cm).stabilization of catheter at back wound under lumbar fascia with reservoir .

Abdominal placement:

Incision is made into anterior abdominal wall, extended down and peritoneum is opened. Then subcutaneous shunt passer is passed and redirected to back incision. shunt catheter stabilized with reservoir at back incision is passed through passer, and inserted into peritoneal cavity. the wound is then closed.After surgery all patients were kept in ward for 4 to 5 days and then discharged to home. All patients were followed up till 1 year, with 2 months interval.Postoperatively clinical outcome was measured by History and Fundus examination and CT brain. Postoperative follow up was clinical with history and Fundoscopy, and radiological with CT brain.All data was collected and put in Performa. All data was analyzed using SPSS version 20. Results were expressed in the form of tables/graphs/charts.

Results

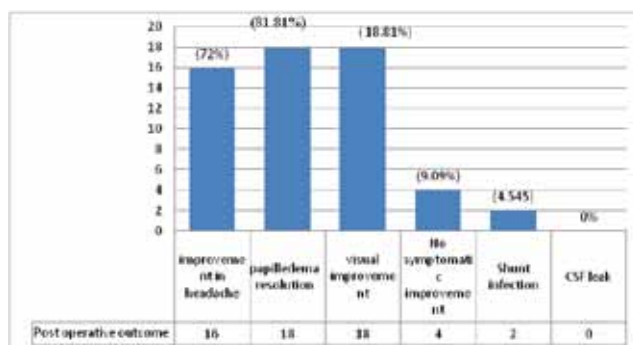
We studied 22 patients with Diagnosed cases of BIH. All patients were female. Age ranged from 18 to 58 with mean of 38 ± 5 years SD. In pre operative signs and symptoms the commonest was headache which was present in all (100%) patients , Visual deterioration in 20(90.90%) patient and all (100 %) these patients had Papilledema. 6(27.7%) patients had vomiting , 6th nerve palsy in 2(9.09%) patients (Table no 1) . All patients were investigated to follow modified dandy criteria. CT brain was done in 10(45.45%) patients. MRI brain with MRV was done in all(100%) patients. CSF manometry showed opening pressure from 28cm of H₂O to 50 cm of H₂O, with mean of 39.19. CSF composition was normal in all patients. MRI brain showed slit ventricles in 3(13.63%) cases. LP shunt was done for all 22(100%) cases. Postoperatively clinical outcome was measured by History and Fundus examination and CT brain uptill 1 years by intervals of 2 months follow up. Headache

improved in 16(72%) patients, Papilledema resolved postoperatively in 18(81.81%) cases and same number of patients 18(81.81%) showed improvement in vision. 4(18%) patients had persistence of symptoms postoperatively. Shunt infection was noticed in 2(9.09%) cases in first 4 weeks which was subsequently managed. CSF leak was noticed in 1(4.54%) case for which shunt revision was done (Graph no 1).

Table no 1; Pre operative signs and symptoms N=22

Pre operative signs and symptoms	No of patients	Percentage of patients
Headache	22	100%
Papilledema	22	100 %
Visual deterioration	20	90.90%
vomiting	6	27.7%
6th nerve palsy	2	9.09%

Graph no 1; Post operative outcome of BIH N=22



Discussion

Benign intracranial hypertension is characterized by Raised CSF pressure of unknown Reason. Resistance to CSF outflow appears to increase, so intracranial pressure also increases. Whether the increased resistance is due to outflow which is obstructed at the level of the arachnoid granulations or outer lymphatic's flow is unclear ,however BIH can result in blindness if inadequately treated but effective options strategies are available 28.The initial criteria suggested by Walter

Dandy have been modified now called modified dandy criteria. Patients who follow these criteria are diagnosed as having the BIH. Laboratory evaluation is normal but there is raised intracranial pressure²⁹.In the review of our 3 years experience with 22 patients with IIH who underwent Lumboperitoneal shunts , we aimed to determine improvement in visual problems after surgery. In our study we had age ranged from 18 to 58 years with mean of 38.and this correlates with Whitely and coworkers who prospectively had peak incidence of disease in 3rd decade of life³⁰. The disease is more common in women of child bearing age. we had all patients female 22(100%) had BIH in three years duration. and explanation is consistent with the hormonal theory for pathogenesis of BIH which states that high incidence among obese women as adipocytes covert androstenedione to estrone which increases CSF production³¹. Study conducted by Yadav YRetal³² also showed this disease in 90.90% patients, which closely correlates to our study. Headache and vision deterioration are common problems in patients with BIH. We had headache in all (100%) patients and vision deterioration in 20(90.90%) patients. It is comparable with study of Corbett and colleagues³³, who also had the same incidence (100 % of cases) in their series which included 20 patients with BIH. There are many surgical treatment options for BIH management which includes Lumboperitoneal shunting, Ventriculoperitoneal shunting, and optic nerve sheath decompression. Cerebrospinal fluid shunting is the most widely performed surgical treatment for BIH and it is useful in the treatment of Papilledema, headache, and visual loss. We did Lumboperitoneal shunting for all(100%) patients. Postoperatively headache and Visual symptoms improved in 16(72%), and 18(81.81%) consecutively. In another international study by Burgett, etal³⁴.described an 82% success rate of postoperative headache relief and visual improvement in patients with LP shunts. So our results are comparable with their results. Purvin VA et al³⁵, had studied 30 patients who underwent LP shunting for treatment of BIH. Out of 14 patients with impaired acuity, 10 eyes (71%) improved after shunting, which is less as compared to our 81%. on subsequent follow up visits 3(13.63%) patients had low pressure headache which was conservatively managed.

References

1. Digre KB, Corbett JJ. Idiopathic intracranial hypertension (pseudotumor cerebri): a

- reappraisal. *Neurologist* . 2001;7:2–67.
2. Radhakrishnan K, Ahlskog JE, Cross SA, Kurland LT, O Fallon WM. Idiopathic intracranial hypertension (pseudotumor cerebri). Descriptive epidemiology in Rochester, Minn, 1976 to 1990. *Arch Neurol*. 1993;50:78–80.
 3. Radhakrishnan K, Thacker AK, Bohlaga NH, Maloo JC, Gerryo SE. Epidemiology of idiopathic intracranial hypertension: a prospective and case-control study. *J Neurol Sci*. 1993;116:18–28.
 4. Durcan FJ, Corbett JJ, Wall M. The incidence of pseudotumor cerebri: population studies in Iowa and Louisiana. *Arch Neurol*. 1988;45:875–7.
 5. Gordon K. Pediatric pseudotumor cerebri: descriptive epidemiology. *Can J Neurol Sci*. 1997;24:219–21.
 6. Durcan FJ, Corbett JJ, Wall M. The incidence of pseudotumor cerebri. Population studies in Iowa and Louisiana. *Arch Neurol*. 1988;45:875–7.
 7. Shaw GY, Million SK. Benign intracranial hypertension: A diagnostic dilemma. *Case Rep Otolaryngol*. 2012;2012:814.
 8. Binder DK, Horton JC, Lawton MT, McDermott MW. Idiopathic intracranial hypertension. *Neurosurg*. 2004;54:538–51.
 9. Biousse V, Bousser MG. Benign intracranial hypertension. *Rev Neurol*. 2001;157:21–34.
 10. Wall M. The headache profile of idiopathic intracranial hypertension. *Cephalalgia*. 1990; 10 : 331–5 .
 11. Ahlskog JE, O'Neill BP. Pseudotumor cerebri. *Ann Intern Med*. 1982;97:249–56.
 12. Smith JL. Whence pseudotumor cerebri? *J Clin Neuro-Ophthalmol*. 1985;5:55–6.
 13. Corbett JJ, Mehta MP. Cerebrospinal fluid pressure in normal obese subjects and patients with pseudotumor cerebri. *Neurology*. 1983;33: 1386–8.
 14. Newborg B. Pseudotumor cerebri treated by rice/reduction diet. *Arch Intern Med*. 1974;133:802–7.
 15. Friedman DI, Ingram P, Rogers MAM. Low tyramine diet in the treatment of idiopathic intracranial hypertension: a pilot study. *Neurology*. 1998;50:45–8.
 16. Corbett JJ, Thompson HS. The rational management of idiopathic intracranial hypertension. *Arch Neurol*, 1989;46:1049–51.
 17. Physicians' Desk Reference, 56th edition. Montvale, NJ: Medical Economics Company, Inc; 2002:2590–5.
 18. Garton HJ. Cerebrospinal fluid diversion procedures. *J Neuroophthalmol*. 2004;24(2): 146–55.
 19. Kesler A, Gadoth N. Pseudotumor cerebri (PTC--an update). *Harefuah*. 2002;141(3): 297–300.
 20. Liu GT, Volpe NJ, Schatz NJ, Galetta SL, Farrar JT, Raps EC. Severe sudden visual loss caused by pseudotumor cerebri and lumboperitoneal shunt failure. *Am J Ophthalmol*. 1996;122(1): 129–131.
 21. Brazis PW: Clinical review: The surgical treatment of idiopathic pseudotumor cerebri (idiopathic intracranial hypertension). *Cephalalgia*. 2008; 28(12):1361–73.
 22. Feldon SE. Visual outcomes comparing surgical techniques for management of severe idiopathic intracranial hypertension. *Neurosurg Focus*. 2007;23(5):43–6.
 23. Sergott RC, Savino PJ, Bosley TM. Optic nerve sheath decompression: A clinical review and proposed pathophysiologic mechanism. *Aust N Z J Ophthalmol*. 1990;18(4):365–73.
 24. Villain MA, Candon E, Arnaud B, Hamard H, Adenis JP. Optic nerve sheath decompression in optic neuropathy complicating idiopathic intracranial hypertension: A new focus. *J Fr Ophthalmol*. 2003;26(2):191–7.
 25. Woodworth GF, McGirt MJ, Elfert P, Sciubba DM, Rigamonti D. Frameless stereotactic ventricular shunt placement for idiopathic intracranial hypertension. *Stereotact Funct Neurosurg*. 2005;83(1):12–6.
 26. Brazis PW. Pseudotumor cerebri. *Curr Neurol Neurosci Rep*. 2004;4(2):111–6.
 27. Brazis PW. Clinical review: The surgical treatment of idiopathic pseudotumor cerebri (idiopathic intracranial hypertension). *Cephalalgia*. 2008; 28(12):1361–73.
 28. Friedman DI, Jacobson DM. Idiopathic intracranial hypertension. *J Neurol Ophthalmol*. 2004;24:139–45.
 29. Vitale S, Eggenberger ER, Miller NR. Lumboperitoneal shunt for the treatment of pseudotumor cerebri. *Neurology*. 1996;46: 1524–30.
 30. Whiteley W., Al Shahi R. CSF opening pressure: Reference interval and the effect of body mass index. *Neurology*. 2006;67(9): 1690–3.
 31. Binder DK, Horton JC, Lawton MT. Idiopathic intracranial hypertension. *Neurosurg*. 2004;5 (3):538–51.
 32. Yadav RM. lumbar Peritoneal Shunt in idiopathic Intracranial Hypertension" *Turkish Neurosurg*. 2012;22(1):21–6.

33. Corbett JJ, Mehta MP. Cerebrospinal fluid pressure in normal obese subjects and patients with pseudotumor cerebri. *Neurology*. 1983;33:1386–8.
34. Burgett RA, Purvin VA, Kawasaki A. Lumboperitoneal shunting for pseudotumor cerebri. *Neurology*. 1997;49:734–9.
35. Purvin VA, Burgett RA, Kawasaki A. Lumboperitoneal shunting for pseudotumor cerebri. *Neurology*. 1997;49:734–9.

Conflict of interest: Author declares no conflict of interest.

Funding disclosure: Nil

Author's contribution:

Naeem ul Haq: Study concept and design, protocol writing, data collection, data analysis, manuscript writing, manuscript review

Naseer Hassan: collection, data analysis, manuscript writing, manuscript review

Muhammad Ishaq; data collection, data analysis, manuscript writing, manuscript review

Muhammad Usman; Study concept and design, data analysis, manuscript writing, manuscript review