



7-2014

# Endovascular treatment of intracranial aneurysms using balloon remodeling technique

Wasey Jilani

*Aga Khan University Hospital,*

Tanveer ul Haq

*Aga Khan University, Karachi*

Follow this and additional works at: <http://ecommons.aku.edu/pjns>



Part of the [Neurology Commons](#)

## Recommended Citation

Jilani, Wasey and Haq, Tanveer ul (2014) "Endovascular treatment of intracranial aneurysms using balloon remodeling technique," *Pakistan Journal of Neurological Sciences (PJNS)*: Vol. 9 : Iss. 3 , Article 11.

Available at: <http://ecommons.aku.edu/pjns/vol9/iss3/11>

# ENDOVASCULAR TREATMENT OF INTRACRANIAL ANEURYSMS USING BALLOON REMODELING TECHNIQUE

Dr. Wasey Jilani<sup>1</sup>, Dr. Tanveer ul Haq<sup>2</sup>

<sup>1</sup> Resident, Department of Radiology, Aga Khan University Hospital.

<sup>2</sup> Professor, Department of Radiology, Aga Khan University Hospital.

Correspondence to Prof Tanveerul Haq, Department of Radiology, Aga Khan University, Karachi. Email: tanveer.haq@aku.edu

Date of submission: June 28, 2014, Date of revision: August 1, 2014, Date of acceptance: August 15, 2014

## ABSTRACT

Endovascular treatment with coils is widely used in the management of intracranial aneurysms. However, this type of treatment can be technically challenging for anatomic reasons, particularly when the neck of the aneurysm is wide or when the dome-to-neck ratio is not favorable. Previous studies described the remodeling technique for extending the indications and feasibility of the endovascular treatment to wide-neck intracranial aneurysms. In remodeling technique, a non-detachable balloon is temporarily inflated in front of the neck of the aneurysm during each coil placement. At the end of the procedure, the remodeling balloon is removed and no device is left in place in the parent vessel unless stent placement is subsequently performed. The remodeling technique can be used in all aneurysm locations but is adopted less frequently in anterior communicating and anterior cerebral aneurysms. Studies have also shown adequate aneurysm occlusion is significantly more frequent in the remodeling group. Despite the fact that aneurysms treated by the remodeling technique are different from aneurysms treated with standard coiling, the safety of both techniques is similar with a higher anatomic efficacy of the remodeling technique. Accordingly, wide use of the remodeling technique can be proposed.

## INTRODUCTION

Endovascular treatment with coils is widely used in the management of intracranial aneurysms. However, this type of treatment can be technically challenging for anatomic reasons, particularly when the neck of the aneurysm is wide or when the dome-to-neck ratio is not favorable. Previous studies described the remodeling technique for extending the indications and feasibility of the endovascular treatment to wide-neck intracranial aneurysms. What is the Remodeling Technique? A non-detachable balloon is temporarily inflated in front of the neck of the aneurysm during each coil placement. At the end of the procedure, the remodeling balloon is removed and no device is left in place in the parent vessel unless stent placement is subsequently performed<sup>2</sup>. In sidewall aneurysms, the balloon is simply placed in the parent vessel in front of the aneurysm neck. In bifurcation aneurysms, the situation is more complex because it is necessary to completely protect the neck to avoid coil protrusion. In this situation, there are several options: 1) Place 1 balloon in the parent vessel and a bifurcation artery. Inflate the balloon sufficiently to completely cover the neck (some balloons are specifically designed for this purpose with a pear shape when inflated). 2) Place two balloons in front of the aneurysm neck. For example, for a basilar tip aneurysm, a balloon is placed in

the basilar artery extending into the posterior cerebral artery and another balloon is placed on the other side. 3) Place a balloon parallel to the neck of the aneurysm by navigating through the circle of Willis anastomosis. For example, in a carotid bifurcation aneurysm, the balloon is not navigated through the ipsilateral carotid artery but through the contralateral one and the anterior communicating artery. This technique is feasible if the anastomoses of the circle of Willis are present and sufficiently large. 4) Place a round balloon mounted on a microcatheter in front of the aneurysm neck. These balloon catheters are no longer available; therefore, this technique can no longer be used. 5) Place a double-lumen microcatheter remodeling balloon. It is placed in front of the neck with the microguidewire inside the neck. The coils are deposited in the aneurysm sac through the second lumen. In bifurcation aneurysms, the best option is decided according to the anatomy of the parent vessel (cervical and intracranial portions), the anatomy of the circle of Willis (confirm that posterior communicating and anterior communicating arteries are present), and the aneurysm anatomy (size and position of the neck, direction of the aneurysm sac, and relations between aneurysm neck and bifurcation branches). Use and Feasibility of the Technique. The remodeling technique can be used in all aneurysm locations but is adopted less frequently in anterior communicating and anterior cerebral aneurysms. The

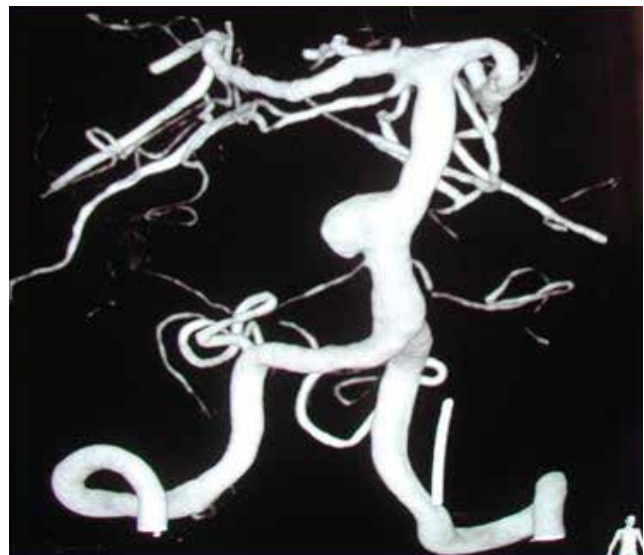navigation in the anterior arterial complex is relatively difficult. However as the availability of newer balloons has improved, navigation in the anterior complex is now easier. Balloon navigation can be difficult in the case of tortuosity of the cervical or intracranial vessels or acute angle of the parent vessel. Another cause of failure of the remodeling technique is a completely unfavorable dome-to-neck ratio with a very wide neck. In this case, the stabilization of coils into the aneurysm sac can be impossible despite inflation of the balloon in front of the neck. Complications The 2 most frequent complications of the endovascular treatment of intracranial aneurysms are thromboembolic events and intraoperative rupture<sup>3,4</sup>. Symptomatic thromboembolic events are possible in a small percentage of cases. In previous studies, symptomatic thromboembolic events were encountered in 4.6% of patients treated with coiling and 4.4%<sup>5</sup> of patients treated with remodeling. Death related to thromboembolic events was reported as 1.2%<sup>6</sup> for patients treated with coiling and 0.4% for patients treated with remodeling. In unruptured aneurysms the rate of thromboembolic events was lower in the remodeling group (5.4% versus 6.2% in coiling group), and the clinical outcome was similar in both groups. In ruptured aneurysms, the rate of thromboembolic events was also similar in both groups (12.7% in coiling group and 11.3% in remodeling group)<sup>7</sup>. The rate of intraoperative rupture has not been evaluated as extensively. In ruptured aneurysms, the clinical outcome was a symptomatic event or death in 2.7% in the coiling group and 1.7% in the remodeling group<sup>8,9</sup>. In unruptured aneurysms, clinical outcome was a symptomatic event or death in 0.6% in coiling group and 0.9% in remodeling group.

## CONCLUSIONS

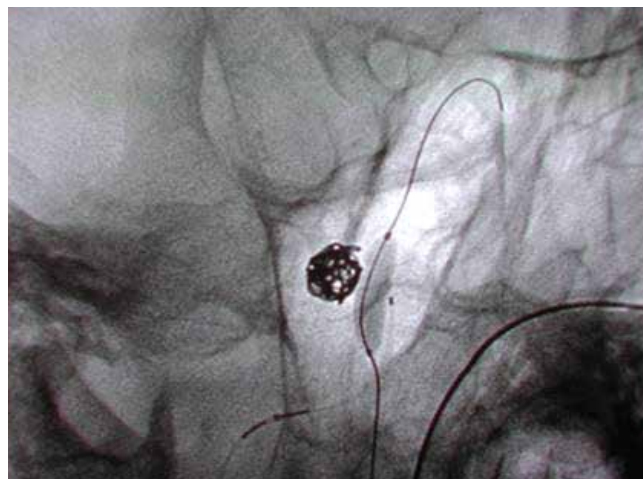
There is a similar safety profile in the standard coiling and the remodeling techniques. The literature search comparing the anatomic results in aneurysms treated by standard coiling and remodeling shows that immediate and follow-up results are better in the remodeling group. Studies have also shown adequate aneurysm occlusion is significantly more frequent in the remodeling group. Despite the fact that aneurysms treated by the remodeling technique are different from aneurysms treated with standard coiling, the safety of both techniques is similar with a higher anatomic efficacy of the remodeling technique. Accordingly, wide use of the remodeling technique can be proposed.

## REFERENCES

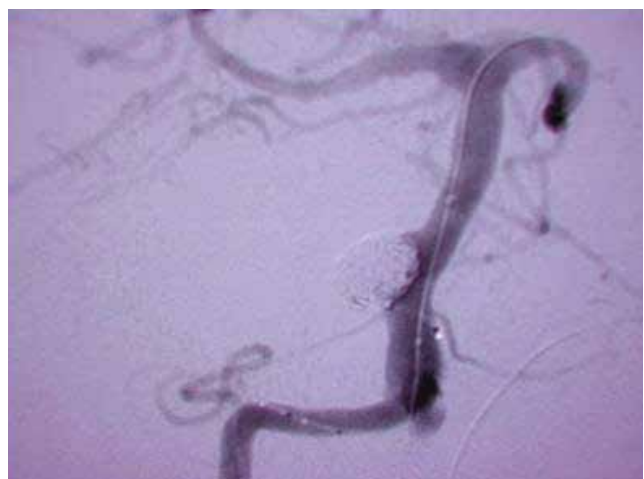1. Moret J, Cognard C, Weill A, et al. The “remodeling technique” in the treatment of wide neck intracranial aneurysms. *Intervent Neuroradiol* 1997;3:21–35



**Figure 1.** Basilar artery Aneurysm



**Figure 2.** Deployment of Coil within the aneurysm



**Figure 3.** Post procedure angiogram showing complete exclusion of the aneurysm.

2. Aletich VA, Debrun GM, Misra M, et al. The remodeling technique of balloon assisted Guglielmi detachable coil placement in wide-necked aneurysms: experience at the University of Illinois at Chicago. *J Neurosurg* 2000;93:388–96
3. Molyneux A, Kerr R, Stratton I, et al, for the International Subarachnoid Aneurysm Trial (ISAT) Collaborative Group. International Subarachnoid Aneurysm Trial (ISAT) of neurosurgical clipping versus endovascular coiling in 2143 patients with ruptured intracranial aneurysms: a randomised trial. *Lancet* 2002;360:1262–63
4. Cottier JP, Pasco A, Gallas S, et al. Utility of balloon-assisted Guglielmi detachable coiling in the treatment of 49 cerebral aneurysms: a retrospective, multicenter study. *AJNR Am J Neuro radiol* 2001;22:345–51
5. Lefkowitz MA, Gobin YP, Akiba Y, et al. Balloon-assisted Guglielmi detachable coiling of wide-necked aneurysms. II. Clinical results. *Neurosurgery* 1999;45:531–37
6. Nelson PK, Levy DI. Balloon-assisted coil embolization of wide-necked aneurysms of the internal carotid artery: medium term angiographic and clinical follow-up in 22 patients. *AJNR Am J Neuro radiol* 2001;22:19–26
7. Layton KF, Cloft HJ, Gray LA, et al. Balloon-assisted coiling of intracranial aneurysms: evaluation of local thrombus formation and symptomatic thromboembolic complications. *AJNR Am J Neuroradiol* 2007;28:1172–75
8. Sluzewski M, Von Rooij WJ, Beute GN, et al. Balloon-assisted coil embolization of intracranial aneurysms: incidence, complications, and angiography results. *J Neurosurg* 2006;105:396–99
9. Malek AM, Halbach VV, Phatouros CC, et al. Balloon-assisted technique for endovascular coil embolization of geometrically difficult intracranial aneurysms. *Neurosurgery* 2000;22:46:1396–406, discussion1406–08

**Conflict of Interest:** Author declares no conflict of interest.

**Funding Disclosure:** Nil

**Author's Contribution:**

**Dr. Tanveerul Haq:** Study concept and design, protocol writing, data collection, data analysis, manuscript writing, manuscript review

**Dr. Wasey Jilani:** Data collection, data analysis, manuscript writing, manuscript review