



7-2014

Analytic study of clinical presentation of intracranial space-occupying lesions in adult patients

Bashir A. Soomro

Neuro Clinic and Care ,Karachi ,Pakistan.

Sameen Khalid

Ziauddin Hospital karachi

Shafaq Alvi

Neuro Clinic and Care ,Karachi ,Pakistan.

Follow this and additional works at: <http://ecommons.aku.edu/pjns>

 Part of the [Neurology Commons](#)

Recommended Citation

Soomro, Bashir A.; Khalid, Sameen; and Alvi, Shafaq (2014) "Analytic study of clinical presentation of intracranial space-occupying lesions in adult patients," *Pakistan Journal of Neurological Sciences (PJNS)*: Vol. 9 : Iss. 3 , Article 2.

Available at: <http://ecommons.aku.edu/pjns/vol9/iss3/2>

ANALYTIC STUDY OF CLINICAL PRESENTATION OF INTRACRANIAL SPACE-OCCUPYING LESIONS IN ADULT PATIENTS

Bashir A. Soomro¹, Sameen Khalid², Shafaq Alvi¹

¹ Neuro Clinic and Care, Karachi, Pakistan.

² Ziauddin Hospital, Shahrah-e-Ghalib, Karachi, Pakistan

Correspondence to: Bashir A. Soomro, 43/ II Zulfikar Street No: 03, Phase VIII DHA, Karachi. Postal Code: 75500. Email: basoomro@gmail.com
 Date of submission: July 5, 2014, Date of revision: September 10, 2014, Date of acceptance: September 22, 2014

ABSTRACT

Background: Intracranial space-occupying lesions can be caused by a variety of disease processes, ranging from neoplasms to non-neoplastic lesions including hematomas, abscesses and vascular malformations. This article provides an overview of varied clinical presentations of patients with intracranial space-occupying lesions. **Methods:** A total of 200 cases of intracranial space-occupying lesions presenting at Neuro Clinic and Care were retrospectively analyzed. Adult patients from all age groups and both genders were included in this study. **Results:** 165 patients (82.5%) had neoplastic lesions while 35 (17.5%) had non-neoplastic lesions. Metastatic lesions from primary tumor elsewhere in the body comprised the most common group with 81 cases (40.5%), followed by meningiomas with 27 cases (13.5%). Males were affected slightly more than females (1:0.8). The most common presenting symptom was headache 87 patients (43.5%), followed by focal symptoms such as numbness, tingling or weakness being present in 80 (40%) and seizures observed in 65 (32.5%). **Conclusion:** The study reviews the wide range of symptoms the patients with intracranial space-occupying lesions present with, the most common being headache, followed by focal symptoms such as numbness, tingling or weakness, seizures and vomiting. Knowledge of these typical as well as atypical patterns of clinical presentation can aid physicians in timely detection and prompt application of diagnostic and therapeutic modalities.

Key Words: Intracranial space-occupying lesions, Primary brain tumors, Clinical presentation.

INTRODUCTION

The term “intracranial space-occupying lesion” refers to neoplasms as well as non-neoplastic lesions. Neoplasms may be benign or malignant and primary or metastatic. Non-neoplastic lesions include hematomas, cerebral abscesses including Toxoplasmosis, cysts including arachnoid cysts, colloid cysts, dermoid cysts, epidermoid cysts, vascular malformations and inflammatory or parasitic masses such as cerebral Amoebiasis and cysticercosis within cranial cavity ⁽¹⁾. Primary malignant tumors of the central nervous system (CNS) account for approximately 2% of all the primary tumors of the human body ^(2, 3). Considerable regional and racial variations play a role in the difference in the incidence and pattern of intracranial neoplastic space-occupying lesions (SOL) throughout the world ⁽¹⁾. In most studies reported from Asian countries, brain tumors occurred mostly during 4th decade of life while in Western countries, during 5th and 6th decades of life ⁽⁴⁻¹³⁾. Incidence of brain tumors in the U.S. is 10 per 100,000 person-years, with a male-female ratio of 6:4 ⁽¹⁴⁾. Primary brain tumors are classified on the basis of their histological appearance and cellular origin⁽³⁾. Primary brain

tumors can be classified as gliomas or non-gliomas. Gliomas account for >80% of primary brain tumors and include astrocytomas, oligodendrogliomas, ependymomas and mixed oligodendroglial and astrocytic tumors. Non-gliomas comprise of benign tumors such as meningiomas and pituitary adenomas as well as malignant tumors such as medulloblastomas, primary CNS lymphomas and CNS germ cell tumors. The most common benign brain tumors are meningiomas, comprising about 20% of primary brain tumors. Astrocytomas including Glioblastoma multiforme (GBM) are the most common malignant brain tumors ^(2,3). Almost half of the brain tumors are primary and the remaining are metastases that have originated outside the CNS. Brain metastases are more common than primary malignant brain tumors and are usually multiple ⁽¹⁴⁾. The most common tumor metastasizing to brain is carcinoma lung followed by carcinoma breast, colonic carcinoma and malignant melanoma. Patients with intracranial space-occupying lesions can present with signs and symptoms that can be generalized or focal (Table 1). Focal symptoms are due to localized brain damage and presentation may indicate location of lesion. These symptoms include weakness, somatosensory loss, visual

Table 1: Presenting Symptoms & Signs in Patients with Intracranial Space-Occupying Lesions			
Generalized Signs & Symptoms	False Localizing & Lateralizing Signs	Localizing Signs & Symptoms	
Headache	CN lesions	Temporal Lobe: Behavioral changes Depersonalization Hallucinations Quadrantanopia Complex partial or generalized seizures	
Nausea, Vomiting	Horner's Syndrome		
Seizures	Cerebellar signs		
Personality changes		Frontal Lobe : Personality changes Hemiparesis Expressive aphasia Anosmia	
Change in mental status			
Memory loss			
Motor deficits			
Sensory deficits		Parietallobe: Spatial disorientation Hemisensory loss Receptive aphasia Hemianopia	
Deficits of speech or vision			
Papilledema			
			Occipital Lobe : Contralateral hemianopia
			Cerebellum: Ataxia Dysmetria Nystagmus
		Cerebello-pontine angle (Acoustic neuroma): Ipsilateral deafness Tinnitus Nystagmus Ipsilateral cerebellar signs Facial and Trigeminal palsies	
		Pituitary tumors:Endocrine symptoms Visual defects	

loss or aphasia and tend to occur in the initial stages of disease. Generalized symptoms occur as the tumor size increases and/or when intracranial pressure (ICP) rises. These symptoms include headache, nausea, vomiting, seizures, neurocognitive symptoms, personality changes and false localizing signs^(3,15-18). Large lesions in some locations in the brain (silent regions) may remain relatively quiescent while a small lesion in dominant hemisphere may drastically impair speech. A space-occupying lesion in CNS may infiltrate and destroy important structures. It can impair cerebrospinal fluid (CSF) flow causing hydrocephalus or it can induce formation of new blood vessels leading to vasogenic edema. In rare instances, intracranial lesions can manifest with unusual symptoms that range from syncopal attacks, vertigo, and vestibular neuritis to local symptoms such as sensory seizures⁽¹⁵⁾, dermatomal hypoesthesia, ulnar neuropathy⁽¹⁵⁾, trigeminal neuralgia⁽¹⁹⁾ and even Parkinsonism⁽²⁰⁾. Physicians could err in their diagnosis and in formulating treatment plans because of these unusual presentations. This study aims to enhance the knowledge regarding the varied clinical presentations of intracranial space-occupying lesions in adult patients to allow early diagnosis and prompt treatment. To the best of our knowledge, current study is one of the few studies conducted in Pakistan regarding the frequency of intracranial space-occupying lesions and the first study from Pakistan demonstrating the spectrum of clinical presentation of intracranial space-occupying lesions in adults.

METHODOLOGY

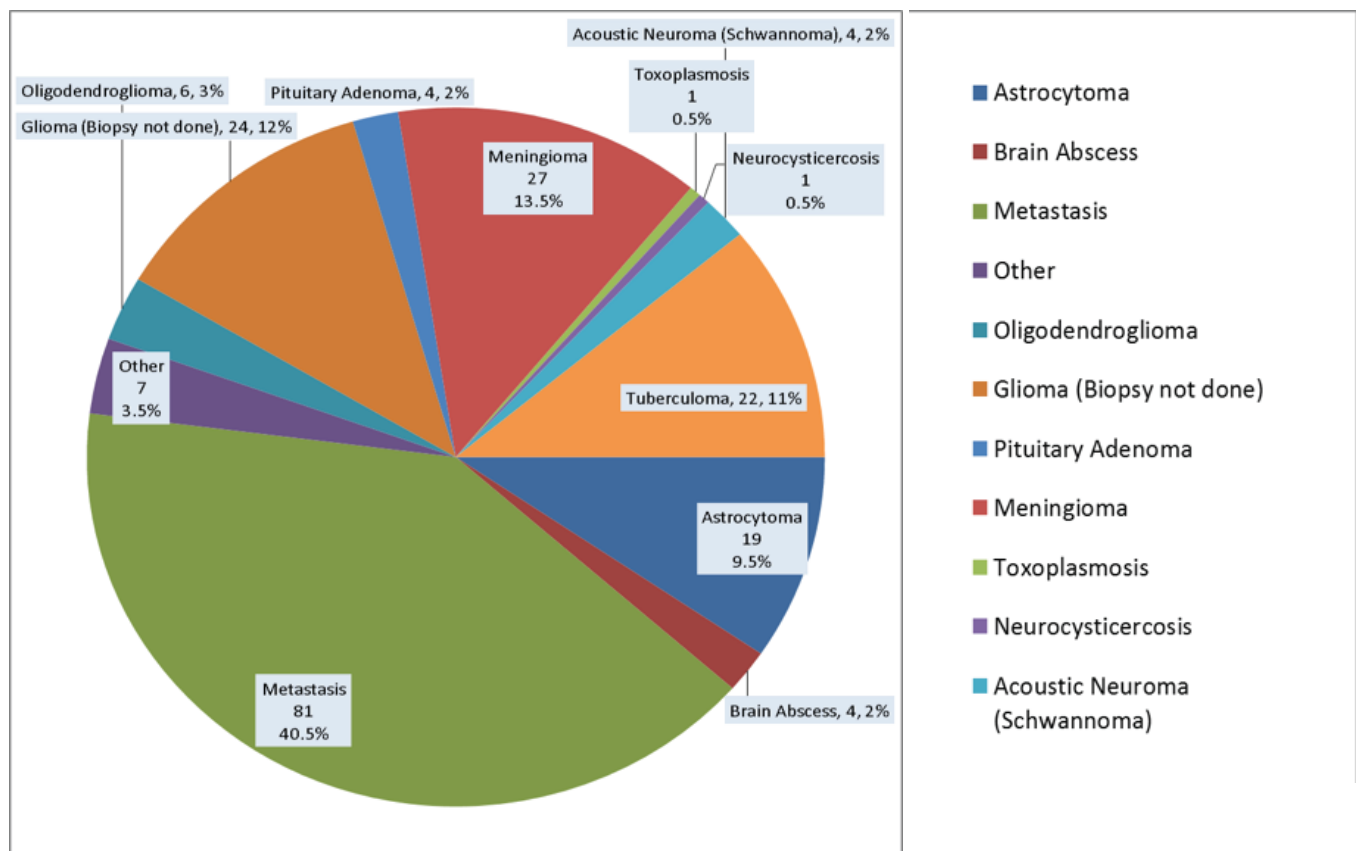
The study was carried out retrospectively in which data from a total of 200 patients with intracranial space-occupying lesions; having been collected over a period of 14 years was reviewed during four months from April 2014 to August 2014 at Neuro Clinic and Care, Karachi, Pakistan. Adult patients from all ages and both genders were included in the study. Diagnosis of intracranial space-occupying lesion was made by either histological examination (biopsy) or radiological examination (computed tomography or magnetic resonance imaging). Data was entered and saved onto SPSS version 20. Before analyzing; data was checked and corrected for any possible error in data entry. Separate frequency and valid percentages were calculated for main categorical variables.

RESULTS

A total of 200 cases of intracranial space-occupying lesions presenting at Neuro Clinic and Care were retrospectively analyzed. Adult patients from all age groups

and both genders were included in this study. The mean age of respondents was 50 (SD +/- 2) years. Male patients constituted 56% (111) and females were 45% (89), giving a male/female ratio of 1:0.8. Figure 1 shows that out of 200 cases of intracranial space-occupying lesions, 82.5% (n=165) were neoplasms, most common of which were brain metastases (40.5%, n=81). Meningiomas ranked second with 27 cases (13.5%) while undifferentiated gliomas (12%, n=24) were third in frequency. Astrocytomas accounted for 9.5% (n=19) cases and oligodendrogliomas were 3% (n=6). Acoustic neuromas (Schwannomas) and pituitary tumors each constituted 2% (n=4) of the lesions. Among the 17.5% (n=35) cases of non-neoplastic lesions, the most common was tuberculomas (11%, n=22) followed by brain abscesses (2%, n=4), neurocysticercosis and toxoplasmosis, each being 0.5% (n=1). Fungal granulomas, arteriovenous malformations and nasopharyngeal mass eroding base of skull comprised 3.5% of cases (n=7). As depicted in Table 2, of all the 200 cases of intracranial space-occupying lesions, the most common clinical presentation was headache (43.5%, n=87) which was characterized in most cases as constant, progressive over a period of weeks or months and moderate to severe in intensity. Focal symptoms such as numbness, tingling and weakness occurred in 40% of cases (n=80). Seizures ranked third in frequency with 32.5% of cases (n=65) and vomiting occurred in 27.5% of cases (n=55). Speech deficit and loss of vision or diplopia ranked fifth and sixth in frequency with 15% (n=30) and 13.5% (n=27) cases respectively. 12% of the patients (n=24) had gait disturbances while 10.5% (n=21) had dizziness. Urine incontinence was found in 7% of the patients (n=14). Progressive decline in cognitive functions occurred in 6.5% (n=13) patients and personality changes were found in 4% (n=8) of the cases. 3.5% of the cases (of acoustic neuroma); (n=7) had hearing deficits while only 1% (n=2) had loss of smell. None of the patients was found to have loss of taste. Other symptoms such as drowsiness, unconsciousness, repeated falls, tinnitus, weight loss, neck pain, dysphagia, generalized weakness and fever occurred in 52.5% of the patients (n=105). While evaluating the patients, motor deficits were found to be the most common presenting sign (Table 3) with 92.5% of the patients (n=185) showing an increase in tone and/or a decrease in power, demonstrating signs of upper motor neuron lesions. Gait disturbances including heel and toe walking were found in more than half of the cases (52.5%, n=105). Sensory impairment in pain, touch, temperature and/or deep pressure sensations that evaluates integrity of anterior/lateral columns was found in 2.5% of the patients (n=5) while sensory impairment in position and vibration sensations evaluating

Figure 1: Distribution of 200 cases of intracranial space-occupying lesions



the integrity of posterior column occurred in 14% (n=28). Cerebellar signs such as nystagmus, positive finger-nose and heel-shin tests and impaired rapid alternating movements were present in 24% (n=48). Level of consciousness was impaired in a quarter of the patients (25%, n=50) with 27.5% of the patients (n=55) not oriented to person, place and/or time. Memory impairment was found in 36.5% of the cases (n=73) and higher cortical functions that were evaluated by serial sevens and calculations were also impaired in 36.5% (n=73). Speech impairment was present in 13.5% of the cases (n=27). Loss of smell occurred in 1.5% (n=3). Cranial nerve II impairment demonstrated by compromised visual acuity, visual fields and by fundoscopic examination showing papilledema was found in 32% (n=64). Pupillary response and extraocular muscle movements were impaired in 12% of the patients (n=24). Facial sensations, corneal reflex and Masseter's bulk and power (demonstrating integrity of cranial nerve V) were impaired in 2.5% (n=5) while cranial nerve VII evaluated by checking facial movements was impaired in 24.5% (n=49). Cranial nerve VIII was evaluated by

hearing tests (Rinne and Weber) and was found to be impaired in 6.5% (n=13). Gag reflex assessing cranial nerves IX and X was absent in 6% of the cases (n=12). Only 2 patients (1%) had impaired active and passive neck movements showing compromised function of cranial nerve XI while tongue mass and movements demonstrating intactness of cranial nerve XII were impaired in 1.5% of the patients (n=3).

DISCUSSION

Both neoplastic and non-neoplastic intracranial space-occupying lesions share features of clinical presentation. In a study involving 100 cases of intracranial space occupying lesions conducted in Lahore, Pakistan,(1) neoplastic lesions comprised 89% of the cases while non-neoplastic lesions were reported to be 11%, which gives a similar proportion as in our study of 200 cases comprising of 82.5% neoplastic and 17.5% non-neoplastic lesions. Males were affected slightly more than females in their study giving a sex ratio of 1.7: 1, which correlates with the results of our study.

Table 2: Frequency of different clinical symptoms of intracranial space-occupying lesions

SYMPTOMS	n	%
Headache	87	43.5%
Seizures	65	32.5%
Vomiting	55	27.5%
Dizziness	21	10.5%
Progressive decline in cognitive functions	13	6.5%
Speech deficit	30	15%
Personality changes	8	4%
Focal signs/symptoms	80	40%
Loss of smell	2	1%
Loss of vision / Diplopia	27	13.5%
Loss of taste	0	0%
Hearing deficits	7	3.5%
Gait disturbances	24	12%
Urine incontinence	14	7%
Others (drowsiness, disorientation, unconsciousness, repeated falls, tinnitus, weight loss, neck pain, dysphagia, generalized weakness, fever)	105	52.5%

Headache, the most common presenting symptom in our study, occurred in 43.5% of the patients. Buckner et al. pointed out that the new onset of headache that is constant, progressive, severe, especially worse in the morning and occurs in association with nausea, vomiting or focal neurological deficits is more characteristic of an intracranial space-occupying lesion⁽²⁾. In patients with pre-existing headaches, a change in the prior headache pattern or an increase in their frequency or intensity suggests presence of an intracranial mass^(2, 21). Headache often occurred in association with other symptoms, including nausea and vomiting (27.5% of the patients), visual disturbances (13.5%), gait disturbances (12%) and dizziness (10.5%). In a retrospective study of 111 patients conducted by Forsyth and Posner, headaches were present in 48% of the patients with primary and metastatic brain tumors, which gives a similar proportion as in our study. Most headaches (77%) were tension-type headache while only some were migraine-type (9%)⁽²¹⁾.

Some locations are more likely to produce headaches, for example, infratentorial and intraventricular tumors were found to cause headache more frequently than a supratentorial tumor, as a result of impaired CSF flow causing hydrocephalus and raised ICP resulting in midline shift^(22, 23). Rapidly growing tumors are more often associated with headache than slow-growing tumors. A study that analyzed signs and symptoms of 279 patients with brain tumors pointed out that in only 1/3rd of the patients the site of the tumor coincided with the lateralization of headache⁽²³⁾. In our study, seizure activity occurred in 32.5% of the patients which is similar in frequency to a study conducted in US by Chandana and Mowva⁽³⁾. Seizure activity has been reported in various studies to be more common in patients with low-grade gliomas^(2,3,15,16). Location of the space-occu-

Table 3: Frequency of different clinical signs of intracranial space-occupying lesions

SIGNS	n	%
Impaired consciousness	50	25%
Not oriented to person, place and/or time	55	27.5%
Impaired memory	73	36.5%
Impaired higher cortical functions	73	36.5%
Impaired speech	27	13.5%
CN I: Impaired sense of Smell	3	1.5%
CN II: Papilledema, abnormalities in visual acuity and visual fields	64	32%
CN III, IV, VI: Restricted Extraocular muscle movements and Abnormal pupillary reflexes	24	12%
CN V: Facial sensation, corneal reflex, masseter 's bulk & power impairment	5	2.5%
CN VII: Impaired Facial movements	49	25%
CN VIII: Hearing Abnormalities (tested Weber and Rinne)	13	6.5%
CN IX, X: Absent gag reflex	12	6%
CN XI: Impaired neck movements	2	1%
CN XII: Abnormalities of tongue mass and movements	3	1.5%
Motor deficits	185	92.5%
Sensory deficits—Anterior/Lateral column (pain, temperature, touch, deep pressure)	5	2.5%
Sensory deficits—Posterior column (position, vibration)	28	14%
Cerebellar signs	48	24%
Gait disturbances	105	52.5%

pying lesion may determine the type of seizure and associated neurologic symptoms. Progressive decline in cognitive functions as the presenting symptom in patients with intracranial space-occupying lesions occurred in 6.5%. Cognitive dysfunction includes changes in memory, orientation, higher cortical functions and speech. Personality changes were reported in 4% of the patients. According to Chandana and Mowa, symptoms of cognitive dysfunction are more likely to herald the presence of an intracranial lesion in dominant hemisphere than in non-dominant hemisphere⁽³⁾. Focal symptoms including motor and sensory deficits such as numbness, tingling and weakness was found in 40% of the patients. Patients with intracranial space-occupying lesions can manifest with unusual symptoms ranging from syncope attacks, vertigo, vestibular neuritis, dermatomal hypoesthesia, psychiatric symptoms to local signs such as sensory seizures and entrapment neuropathy. Our study demonstrated some interesting symptoms that patients with intracranial SOLs may present with. These include loss of smell (1%), hearing deficits (3.5%) and speech deficits (15%). Similarly, trigeminal neuralgia has been reported as the initial manifestation of temporal glioma. The patients presented with episodic, lancinating facial pain. These intracranial supratentorial gliomas occurred especially in young patients. In our study, functions of trigeminal nerve such as facial sensations, corneal reflex and Masseter's bulk and power were impaired in 2.5% (n=5). Because Glioblastoma Multiforme (GBM) is the most common primary brain tumor, it has presented in a number of unusual ways such as ulnar neuropathy, vertigo and syncopal attacks⁽¹⁶⁾, musicogenic epilepsy and reflex epilepsy⁽²⁴⁻²⁶⁾, pseudo-foreign language syndrome^(27, 28), unusual pain syndrome⁽²⁸⁾ and unusual personality changes e.g. hypersexuality and anorexia nervosa^(27,29,30). GBM of the pineal gland (which is extremely rare at this location), has been reported to present with hydrocephalus due to compression of the aqueduct of Sylvius and visual disturbances e.g. horizontal nystagmus and CN VI palsy⁽³¹⁾. Parkinsonism has also been described as a presenting feature of intracranial space-occupying lesions. Tumors that infiltrate or compress striatum or substantia nigra may present with features of Parkinsonism. Meningiomas are the most common histological type that can present with it, particularly those with a supratentorial localization⁽²⁰⁾. Intracerebral schwannomas, in our study, made up 2% of all intracranial space-occupying lesions. These tumors commonly presented with seizures, headache, nystagmus, tinnitus, hearing loss, facial or trigeminal palsies. In rare instances, this tumor has been reported to present as classic temporal lobe epilepsy⁽³³⁻³⁶⁾. Intracranial space-occupying lesions can also present with central pain. Patients with meningioma, low-grade astrocytoma, brain abscess or arteriovenous malformation causing central pain due to compression of parietal cortex have been reported in

literature. Thalamic tumors have also been reported as a cause of central pain⁽³⁷⁾.

REFERENCES

1. Butt ME, Khan SA, et al. "Intra-cranial Space Occupying Lesions: A Morphological Analysis." *Biomedica* Vol.21, 2005 Jan.-Jun./Bio-6.doc(A).
2. Buckner JC, Brown PD, O'Neill BP, et al. "Central Nervous System Tumors." *Mayo Clin Proc.* 2007 October;82(10):1271-1286.
3. Chandana SR, Mowa S, Arora M, et al. "Primary Brain Tumors in Adults." *Am Fam Physician.* 2008;77(10):1423-1430.
4. Jamjoom ZAB. "Pattern of intra-cranial space occupying lesions: experience at King Khalid University Hospital." *Ann Saudi Med*, 1989;9:3-10.
5. Darrel F, Weinman. "Incidence and Behaviour Pattern of Intra-cranial Tumours in Ceylon." *International Surgery.* 1973; 58: 548-54.
6. Wen-Qing QQ, Shi-Jow, Qing-sheng T, et al. "Statistical analysis of central nervous system tumours in China." *J. Neurosurg.* 1982; 56⁽⁴⁾: 555-64.
7. Dastur DK, Lalitha VS, Prabhakar V. "Pathological analysis of intra-cranial space-occupying lesions in 1000 cases including children: 1. Age, sex and pattern; and tuberculomas." *J Neurol Sci.* 1968; 6: 575-92.
8. Ramamurthi B. "Intra-cranial tumors in India: incidence and variations." *International Surgery.* 1973; 58⁽⁸⁾: 542-47.
9. Ranganayakulu Y, Khurana P, Binitie OP, Rohatgi SM, Venkataramana B, Facharzt M.Y.H. "Pattern of intracranial neoplasms in Asir Area; Experience in Asir central Hospital." *Annals of Saudi Med.* 1994; 14: 166.
10. Ahmed Z, Muzaffar S, Kayani, N, Pervez S, Husainy AS, Hasan SH. "Histological Pattern of central nervous system neoplasms." *J Pak Med Assoc.* 2001 April; 51 (4): 154-7.
11. Zuelch KH. "Brain tumors. Their biology and their pathology" 2nd ed. New York Springer. 1965:62-88.
12. Zimmerman HM. "Brain tumors; Their incidence and classification in man and their experimental production." *Ann N.Y. Academy of sciences.* 1969; 159: 337-59.
13. Walker AE, Robins M, Weinfeld ED. "Epidemiology of brain tumors: the national survey of intracranial neoplasms." *Neurology.* 1985;35(2):219-26.
14. Lu-Emerson C, Eichler AF. "Brain Metastases." *Continuum (Minneapolis).* 2012 Apr; 18⁽²⁾: 295-311

15. Schneider T, Mawrin C, Scherlach C, et al. "Gliomas in adults." *DtschArztebl Int.* 2010 Nov;107(45):799-807.
16. Sanli AM, Turkoglu E, Dolgun H, Sekerci Z. "Unusual manifestations of primary Glioblastoma Multiforme: A report of three cases." *SurgNeurol Int.* 2010 Dec 22;1:87.
17. Newton HB. "Primary brain tumors: review of etiology, diagnosis and treatment." *Am Fam Physician.* 1994 Mar;49(4):787-97.
18. Kaba SE, Kyritsis AP. "Recognition and management of gliomas." *Drugs.* 1997 Feb;53(2):235-44.
19. Khalatbari M, Amirjamshidi A. "Trigeminal neuralgia as the initial manifestation of temporal glioma: Report of three cases and a review of the literature." *SurgNeurol Int.* 2011;2:114.
20. Salvati M, Frati A, Ferrari P, Verrelli C, Artizzu S, Letizia C. "Parkinsonian syndrome in a patient with a parietal meningioma: case report and review of the literature." *ClinNeurolNeurosurg.* 2000 Dec;102(4):243-245.
21. Forsyth PA, Posner JB. "Headaches in patients with brain tumors: a study of 111 patients." *Neurology.* 1993 Sep; 43(9):1678-83.
22. Purdy RA, Kirby S. "Headaches and brain tumors." *NeurolClin.* 2004 Feb.;22(1):39-53.
23. Pfund Z, Szapary L, et al. "Headache in intracranial tumors." *Cephalalgia.* 1999 Nov.; 19(9):787-90.
24. El Bouzidi K, Duncan S, Whittle IR, Butler CR. "Lesional reflex epilepsy associated with the thought of food." *Neurology.* 2010;74:610-2.
25. Green JB. "Pilotomotor seizures." *Neurology.* 1984;34:837-9.
26. Marchini C, Romito D, Lucci B, Del Zotto E. "Fits of weeping as an unusual manifestation of reflex epilepsy induced by speaking: Case report." *ActaNeurolScand.* 1994;90:218-21.
27. Filley CM, Kleinschmidt-DeMasters BK. "Neurobehavioral presentations of brain neoplasms." *West J Med.* 1995;163:19-25.
28. Ojemann JG, Miller JW, Silbergeld DL. "Preserved function in brain invaded by tumor." *Neurosurgery.* 1996;39:253-8.
29. Burns JM, Swerdlow RH. "Right orbitofrontal tumor with pedophilia symptom and constructional apraxia sign." *Arch Neurol.* 2003;60:437-40.
30. Lin L, Liao SC, Lee YJ, Tseng MC, Lee MB. "Brain tumor presenting as anorexia nervosa in a 19-year-old man." *J Formos Med Assoc.* 2003;102:737-40.
31. Gasparetto EL, Warszawiak D, Adam GP, Bleggi-Torres LF, de Carvalho Neto A. "Glioblastoma multiforme of the pineal region: case report." *ArqNeuropsiquiatr.* 2003 Jun;61(2B):468-72.
32. Krauss JK, Paduch Th, Mundiger F, Seeger W. "Parkinsonism and rest tremor secondary to supratentorial tumours sparing the basal ganglia." *ActaNeurochir.(Wien).* 1995;133:22-29
33. Haga Y, Shoji H, et al. "Intracerebral Schwannoma: Case Report." *Neurol Med Chir (Tokyo).* 1997. 37:551-555.
34. Guha D, Kiehl TR, Krings T, Valiante TA. "Intracerebral schwannoma presenting as classic temporal lobe epilepsy." *J Neurosurg.* 2012 Jul;117(1):136-40.
35. Kasantikul V, Brown WJ, Cahan LD. "Intracerebral neurilemmoma." *J NeurolNeurosurg Psychiatry* 44:1110-1115,1981.
36. Van Rensburg MJ, Proctor NS, Danziger J, Orelowitz MS. "Temporal lobe epilepsy due to an intracerebral Schwannoma: case report." *J Neurol Neurosurg Psychiatry* 38:703-709,1975.
37. Amancio EJ, Peluso CM, et al. "Central pain due to compression of brain tumor by parietal cortex." *ArqNeuro-Disord.* vol.60 no.2B St. Paul June 2002.

Conflict of Interest: Author declares no conflict of interest.

Funding Disclosure: Nil

Author's Contribution:

Dr. Bashir Soomro: Study concept and design, protocol writing, data collection, data analysis, manuscript writing, manuscript review

Dr. Sameen Khalid: Data collection, data analysis, manuscript writing, manuscript review
Dr. Shafaq Alvi: Study concept and design, protocol writing, data collection, data analysis, manuscript

Dr. Shafaq Alvi: Study concept and design, protocol writing, data collection, data analysis, manuscript writing, manuscript review