



THE AGA KHAN UNIVERSITY

eCommons@AKU

Section of Urology

Department of Surgery

2014

Functional and clinical outcome of ileal (Studer) neo-bladder reconstruction: Single centre experience from Pakistan

Syed M. Nazim
Aga Khan University

Muhammad Hammad Ather
Aga Khan University, hammad.ather@aku.edu

Farhat Abbas
Aga Khan University, farhat.abbas@aku.edu

Follow this and additional works at: https://ecommons.aku.edu/pakistan_fhs_mc_surg_urol



Part of the [Surgery Commons](#), and the [Urology Commons](#)

Recommended Citation

Nazim, S. M., Ather, M. H., Abbas, F. (2014). Functional and clinical outcome of ileal (Studer) neo-bladder reconstruction: Single centre experience from Pakistan. *Journal of the College of Physicians and Surgeons Pakistan*, 24(8), 586-590.

Available at: https://ecommons.aku.edu/pakistan_fhs_mc_surg_urol/24

Functional and Clinical Outcome of Ileal (Studer) Neo-bladder Reconstruction: Single Centre Experience from Pakistan

Syed M. Nazim, M. Hammad Ather and Farhat Abbas

ABSTRACT

Objective: To determine the medium and long-term outcome of orthotopic continent urinary diversion with ileal (Studer) neo-bladder following radical cystectomy.

Study Design: Case series.

Place and Duration of Study: Department of Surgery, The Aga Khan University Hospital, Karachi, from January 1998 to September 2010.

Methodology: Thirty eight patients underwent radical cystectomy for invasive bladder tumor with ileal neo-bladder (Studer type) reconstruction. Peri-operative and late complications, functional outcome of neo-bladder, urinary continence, metabolic and upper urinary tract status and overall survival were evaluated in all patients.

Results: A total of 29 patients (23 males and 6 females) with mean age of 59 ± 12 years were included for the final analysis. The mean duration of surgery (both radical cystectomy and urinary diversion) was 520 ± 70 minutes. Peri-operative complication rate was 24% (n=7) with surgical site infection in 4 patients, sepsis in 1 patient and 2 had uretero-ileal leak. At 6 months follow-up, 22 patients were fully continent while 7 patients had minimal stress / nocturnal incontinence. The continence rate was 93% (n=27) at one year follow-up. The mean capacity of neo-bladder at 6 months was 384 ± 66 mLs. The late complication rate was 17% (n=5). Three patients developed anastomotic stricture requiring transurethral incision of neo bladder neck, one formed stone in neo-bladder and one developed incision hernia. All patients had preserved renal functions on follow-up. The survival rate was 80% (n=23) at a median follow-up of 66.4 ± 36 months. Two patients developed local recurrence and four developed distant metastasis.

Conclusion: Studer ileal neo-bladder is a safe and effective option for urinary diversion in select patients with good oncological and functional outcomes comparable to contemporary literature, even in a low volume center.

Key Words: Bladder cancer. Radical cystectomy. Neo-bladder. Orthotopic diversion. Studer.

INTRODUCTION

Radical cystectomy with urinary diversion is considered as a gold standard treatment for muscle invasive and high grade non-muscle invasive bladder cancer refractory to BCG treatment. Incontinent urinary diversion (like ileal conduit) has historically been the favored option for most patients. However, in recent years, reconstruction of a continent bladder substitute (orthotopic neo-bladder) has become a more desirable and alternative option to ileal conduit.^{1,2}

Orthotopic neo-bladders represent the most physiological bladder substitute after cystectomy for malignancy both in men and women because they share many features similar to the original bladder including excellent continence, adequate capacity and low pressure system.² These reconstructions also offer a near normal voiding function, easier urethral surveillance and superior body image to the patients.³

With the refinements of surgical techniques and more experience, the morbidity and mortality has decreased considerably over time.^{2,4} Because of differences in local custom, social habits and religious practices, the functional outcome may differ between western and Asian patients. Similarly, presence of incontinent stoma may exclude Muslim patients from performing their religious practices.⁵

Since urinary continence and voiding function are the two most important quality of life issues for patients after bladder substitution, this type of reconstruction is now a favorable option after cystectomy. Studer *et al.* described a low pressure bladder substitution using a spherical reservoir in 1989.⁶ This reservoir provides an excellent continence and voiding function with low rate of metabolic problems and preservation of upper urinary tract anatomy and renal function.

Radical cystectomy and ileal neo-bladder formation is regarded as one of the most complex, technically demanding and morbid urological procedures in terms of both ablation and reconstruction.⁷ It is now well known that surgical therapy for bladder cancer has a volume-outcome relationship.⁸ A good oncological and functional outcome with low rate of complications has been reported in centers where surgery is being done very frequently and by a high volume surgeon.⁹

Department of Surgery, The Aga Khan University, Karachi.

Correspondence: Prof. Farhat Abbas, The Hussein Cumber Professor (Urology), Department of Surgery, The Aga Khan University, Karachi.

E-mail: farhat.abbas@aku.edu

Received: September 01, 2012; Accepted: April 19, 2014.

The aim of this study was to determine the outcome of patients with ileal (Studer) neo-bladder re-construction with regard to the operative and peri-operative details, long-term clinical outcome, complications and functional results.

METHODOLOGY

This is a surgical series of more than 13 years duration from January 1998 to September 2010. All patients with T2-T4aN0M0 (TNM classification 1997) transitional cell carcinoma of bladder or Bacillus Calmette-Geurin (BCG) resistant T1G3 tumor with a minimum one year follow-up were included in the study. Peri-operative, early (3 months or less) or late (more than 3 months post-operative) complications, functional outcome of neo-bladder viz. urinary continence and voiding pattern, metabolic and upper tract status and oncological outcome were evaluated in all patients.

All patients who were rendered fit for prolonged surgery with normal renal functions (serum creatinine < 1.3 mg/dl) and who could void spontaneously without any assistance or any other voiding dysfunction were included in the study. They were counselled and informed about the procedure and possibility of an ileal conduit formation and had a stoma counselling by a stoma care nurse. Men with tumor involvement of prostatic urethra and women with extension of tumor to bladder neck region or anterior vaginal wall were excluded. Similarly, patients who were dependents on others or belonging to remote areas or without appropriate intellectual capability or manual dexterity were not considered suitable for the procedure.

Pre-operative mechanical bowel preparation was done. Standard radical cystoprostatectomy in men or cystectomy with anterior exenteration in women with bilateral standard pelvic lymph node dissection was performed. A cystoscopic (visual) assessment of tumor free status of urethra / bladder neck was done in 13 patients while in 16 patients it was determined by frozen section histo-pathological examination. Adequate urethral stump was left. Studer type neo-bladder was constructed by isolating a 54 - 60 cms segment of small bowel approximately 20 cms proximal to ileo-cecal valve as described by Studer.⁶

The distal 40 cm of this segment was opened at the anti-mesenteric border and it was made into a spherical reservoir consisting of four cross- folded de-tubularized segments by using single layer sero-muscular running suture with 3 - 0 braided polyglactin (vicryl). A direct uretero-ileal anastomosis was carried out bilaterally over a feeding tube via an end-side fashion on the afferent iso-peristaltic segment (chimney) which functions as an anti-reflux mechanism to protect the upper urinary tract. The reservoir was anastomosed over its most dependent part by approximating about 8 mm hole with

urethral stump over a 20 Fr urethral silicon catheter using 5 - 6 interrupted polydioxanone (PDS) sutures without tension in a mucosa everting fashion. Another 16 - 20 Fr catheter was placed as a cystostomy tube in the reservoir before completing its closure and brought out through a separated stab over abdominal wall.

A pouchogram was routinely performed after 3 weeks of surgery (Figure 1). Patients were instructed to start on regular timed voiding every 3 hourly in sitting or squatting position by relaxing the pelvic floor assisted by abdominal straining. Pelvic floor (Kegel) exercises and intermittent catheterization to manage mucous by saline irrigation was also taught.

Patients were followed-up within the first month, then after every 3 months for first 2 years, 6 monthly for year 3 and 4 and annually thereafter. The evaluation was done by clinical history, physical examination, urinalysis and culture sensitivity, blood chemistry and imaging by renal ultrasonography on each visit and with abdominal and pelvic CT scan and chest X-ray annually or more.

We do not perform routine uro-dynamic studies to determine the functional outcome in all the patients. Continence status was evaluated by interviewing the patients on each visit and they were considered fully continent when they were completely dry during day and night without any stress incontinence and need for protection by pads, condom catheter or medications. Voiding was classified into 3 categories i.e. voiding without any assistance, voiding with CIC (Clean intermittent catheterization) assistance and voiding with CIC alone. CIC was recommended to the patients with post void residual urinary volume of > 150 mLs.

The collected data was analyzed on Statistical Package for Social Sciences (SPSS) version 17. Continuous variables were presented by mean and standard deviation, while frequency and percentage was given for categorical variables.

RESULTS

A total of 38 patients underwent radical cystectomy with ileal (Studer) neo-bladder reconstruction during the study period. Twenty nine patients (76%) with complete data were included in the final analysis. The mean age was 59 ± 12 , 28 - 76 years with 23 male and 6 female patients. Two patients had neo-adjuvant chemotherapy. The mean duration of surgery was 520 ± 70 (390-680) minutes and mean estimated blood loss was 1250 ± 370 (750 - 4500) mLs. Mean 2.3 ± 1.1 unit packed red cells were transfused to patients. Majority ($n = 24, 83\%$) of patients had clinical stage T2b disease. None of the patients had concomitant prostatic cancer or positive urethral stump margins. The mean number of lymph nodes removed was 14 ± 3 (8 - 23) and only two patients had positive lymph node(s) on final histopathology.

At 6 months of follow-up, 22 (76%) patients were fully continent. The day time continence rate was 93% (n = 27) and night time continence 82% (n= 24) at one year follow-up. Twenty six patients (90%) were able to empty their neo-bladder by relaxation of urethral sphincter mechanism and / or passive expression of the reservoir by abdominal straining.

The mean capacity of neo-bladder at one year was 384 ± 66 (290 - 520) mLs with minimal post-void residue (PVR) as determined by catheterization after voiding. All patients demonstrated good urinary flow on Uroflowmetry (UFM, Table I).

The peri-operative complication rate was 27% (n=8, Table II). None of our patients developed bowel obstruction, deep venous thrombosis (DVT) or symptomatic lymphocele. The late complication rate was 17% (n=5) with 3 patients developed anastomotic stricture requiring bladder neck incision (BNI), one formed stone in the neo-bladder and one developed incisional hernia.

Table I: Functional outcome of Ileal (Studer) neo-bladder.

Parameter	Mean \pm SD n (%)
Continence (6 months)	
Fully continent	22 (76%)
Stress incontinence	3 (10%)
Nocturnal incontinence	4 (14%)
Continence (1 year)	
Day time full continence	27 (93%)
Night time continence	24 (83 %)
Voiding function (1 year)	
Spontaneous	26 (90%)
CISC assisted	2 (7%)
CISC dependant	1 (3%)
Permanent catheterization	Nil
Neo bladder capacity (mL)	384 ± 66 (290-520)
Post void residue (mL)	46 (0-200)
Qmax (mL/sec) on UFM	14.5 ± 2.6 (10-22)

UFM = Uroflowmetry; CISC = Clean intermittent self catheterization.

During follow-up, nearly 79% (n=23) of patients had alkalinizing medications (supplemental soda bicarbonate) and none of the patients showed any metabolic abnormalities or deterioration of renal functions. The

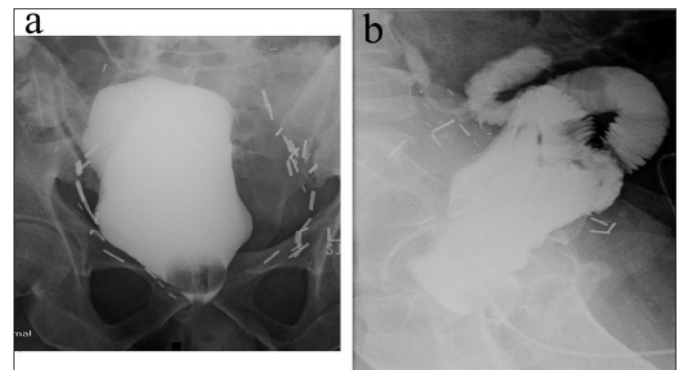


Figure 1 (a,b): Pouchogram of 2 patients (a) Anteroposterior (b) Lateral view showing good capacity and no leakage of contrast or reflux into the ureters.

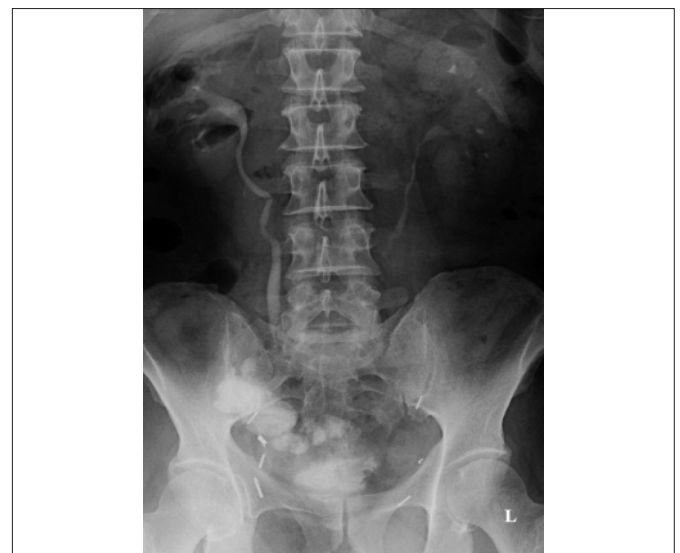

Figure 2: IVU of a patient performed one year after surgery showing preservation of upper urinary tract.

Table II: Complications of radical cystectomy with ileal (Studer) neo-bladder.

Complications	Number of patients (%)	Conservative treatment	Surgical treatment	Modified Clavian system grading
Early complications (< 3 months)	8/29 (27%)	7 (24%)	1 (3.5%)	-
Neo-bladder related	Uretero-ileal leak 2 (7%)	2 (7%)		1
	Ileo-urethral anastomotic stricture 0	--	--	
Neo-bladder unrelated	Surgical site infection 4 (14%)	4 (14%)		2
	Abdominal sepsis 1 (3.5%)	1 (3.5%)		2
	Abdominal wound dehiscence 1 (3.5%)		1 (3.5%)	3b
	Intestinal obstruction 0	--	--	
	Deep venous thrombosis 0	--	--	
	Lymphocele formation 0	--	--	
Late complications (after 3 months)				
Neo-bladder related	Anastomotic stricture 3 (10%)		BNI 3 (10%)	3b
	Urosepsis/ Pyelonephritis	3 (10%)	3 (10%)	2
	Neo bladder stone formation 1 (3.5%)		1 (3.5%)	3b
	Hyperchloremic acidosis 0	--		
Neo-bladder unrelated	Incisional hernia 1 (3.5%)		1 (3.5%)	3b

upper tract evaluation showed only mild hydronephrosis and hydro-ureter on follow-up (Figure 2). Three patients developed uro-sepsis/pyelonephritis requiring hospitalization during long-term follow-up.

Regarding the survival and oncological outcome, there was no peri-operative mortality and at a median follow-up of 66.4 ± 36 (12 - 144) months, 80% (n=23) of patients remained alive without any local recurrence or distant metastases. Two patients developed local recurrence; one requiring total penectomy with urethrectomy and permanent supra-pubic catheterization in the reservoir and other required urethrectomy with resection of reservoir and conversion of afferent tubular segment into an ileal conduit. Four patients developed distant metastases.

DISCUSSION

Various bowel segments including ileum, ascending colon, sigmoid colon, stomach and composite reservoirs formed from combination of the above have been used to form different types of neo-bladder in an attempt to provide better clinical and functional outcome, however, the type of neo-bladder providing most favorable satisfaction to the patients is still controversial. Orthotopic neo-bladder anastomosed to the native urethra allows patients to void naturally without any need for continent or incontinent stoma.

In 2007, a WHO consensus conference report¹⁰ on bladder cancer reported the current status of urinary diversion after cystectomy for bladder cancer. This meta-analysis which included over 7000 patients showed that frequency of neo-bladder formation after radical cystectomy was 47%, making this option the diversion of choice.

In this part of the world, there are several hurdles to accept stoma as a urinary diversion because of interference with daily activities, psychological trauma and loss of body image. Similarly, many Muslim patients believe that presence of an incontinent stoma e.g. an ileal conduit prohibit them from performing their religious activities. Stoma also adds to cost because of frequent change of appliances.

Because of ease of construction, low storage pressure and low mucous production, ileum has now become the bowel segment of choice as compared to the large intestine.¹¹ Ileal (Studer) neo-bladder is the one which provides the largest capacity of all reservoirs and functional data has shown that this capacity provides the improved voiding pattern and continence.¹²

Because of differences in the definition of continence among various studies, it is difficult to compare the outcome between them. Here continence was defined as a state of complete dryness without the need of protective pads, appliances or medications. The

reported day time continence in large studies has ranged b/w 80 - 100% and night time b/w 86 - 97%.^{2,10,13-15} The continence rate in this study is similar to the previously reported ones.

Ileal neo-bladders have been shown to have better overall continence especially nocturnal continence compared to sigmoid neo-bladder in various studies.^{13,16} Our patients had a better night time continence rate. This is because of the relative younger age of patients in this cohort. Reported studies have shown that older age especially > 70 years has an adverse effect on night time continence.^{12,16}

The importance in these patients to void by clock especially by nocturnal alarm-clock was also emphasized which not only prevents over-filling and incontinence but also checks the formation of large capacity (floppy) reservoir with problems in complete emptying. In addition to this regular and timely voiding, the training of pelvic floor muscles by Kegel exercises prevents incontinence and ensures proper voiding in our patients.

Voiding dysfunction is probably the most important issue which adversely affects patients' postoperative satisfaction. Steers *et al.* reported a review of over 2000 patients and has shown that 4 - 25% of patients with orthotopic bladder require intermittent catheterization to completely empty their bladders.¹³

The proportion of patients in this study who could void spontaneously and did not require CIC was 90% and only one patient required it on regular basis. The mean post-void residue was also very low which also reflects the good ability to completely evacuate the neo-bladder.

There was no long-term deterioration of renal function, both structurally and functionally. The plausible explanation is that urine usually remains sterile within the closed system of orthotopic substitute and the dynamic anti-reflux properties of afferent ileal loop prevent reflux nephropathy and structural deterioration.

Because of improvement in surgical techniques and better peri and postoperative care, both the morbidity and mortality after radical cystectomy has decreased considerably during last 10 - 20 years. None of these patients had peri-operative mortality which is reported to be between 0.8 - 2.0% in other studies.^{17,18} The complication rate reported after neo-bladder formation is 24 - 48% in the larger series.^{15,17,19,20} These patients had comparable results.

There are many limitations of this study. First, it was a retrospective chart review with small number of patients. The functional properties of any bladder substitute can be better addressed by urodynamic investigations including cystometry, urethral pressure profilometry and pressure flow studies. Urodynamics were not routinely performed in Studer neo-bladder patients except for uroflowmetry (UFM) which showed good flow. Although

these patients showed an overall good continence and voiding which have a positive impact on their quality of life, health related quality of life could not be objectively defined in this study because of its retrospective nature.

CONCLUSION

Studer ileal neo-bladder was a safe and effective option for urinary diversion after radical cystectomy in properly selected patients with good oncological and functional outcomes which is comparable to contemporary literature. We recommend this form of continent diversion as the preferred option in appropriately selected cases following radical cystectomy.

REFERENCES

1. Meyer JP, Fawcett D, Gillatt D, Persad R. Orthotopic neo-bladder reconstruction: what are the options? *BJU Int* 2005; **96**:493-7.
2. Hautmann RE. Urinary diversion: ileal conduit to neo-bladder. *J Urol* 2003; **169**:834-42.
3. Meyer JP, Blick C, Arumainayagam N, Hurley K, Gillatt D, Persad R, *et al.* A three-centre experience of orthotopic neo-bladder reconstruction after radical cystectomy: revisiting the initial experience, and results in 104 patients. *BJU Int* 2009; **103**:680-3.
4. Turner WH, Bitton A, Studer UE. Reconstruction of the urinary tract after radical cystectomy: the case for continent urinary diversion. *Urology* 1997; **49**:663-7.
5. Lee KT, Li MK, Cheng WS, Foo KT. The impact of a modified ileal neo-bladder on the lifestyle and voiding patterns in Asian patients. *Br J Urol* 1998; **81**:705-8.
6. Studer UE, Ackermann D, Casanova GA, Zingg EJ. Three years' experience with an ileal low pressure bladder substitute. *Br J Urol* 1989; **63**:43-52.
7. Montie JE. Technique of radical cystectomy in the male. In: Marshall FF, Kavoussi LR, McAninch JW, Peters CA, editors. Textbook of operative urology. Philadelphia, PA: W.B. Saunders Company; 1996. p. 396- 407.
8. Fradet V, Allareddy V, Aaronson DS, Konety BR. Is the complication rate of radical cystectomy predictive of the complication rate of other urological procedures? *J Urol* 2009; **181**:1054-9; discussion 1059-60.
9. Hautmann RE, Botto H, Studer UE. How to obtain good results with orthotopic bladder substitution: the 10 commandments. *Eur Urol Suppl* 2009; **8**:712-7.
10. Hautmann RE, Abol-Enein H, Hafez K, Haro I, Mansson W, Mills RD, *et al.* Urinary Diversion; World Health Organization (WHO) consensus conference on bladder cancer. *Urology* 2007; **69**:17-49.
11. Hautmann RE, Volkmer BG, Schumacher MC, Gschwend JE, Studer UE. Long-term results of standard procedures in urology: the ileal neo-bladder. *World J Urol* 2006; **24**:305-14.
12. Hautmann RE, de Petriconi R, Gottfried HW, Kleinschmidt K, Mattes R, Paiss T. The ileal neo-bladder: complications and functional results in 363 patients after 11 years of follow-up. *J Urol* 1999; **161**:422-7.
13. Steers WD. Voiding dysfunction in the orthotopic neo-bladder. *World J Urol* 2000; **18**:330-7.
14. Leissner J, Stein R, Hohenfellner R, Köhl U, Riedmiller H, Schröder A, *et al.* Radical cystoprostatectomy combined with Mainz pouch bladder substitution to the urethra: long-term results. *BJU Int* 1999; **83**:964-70.
15. Studer UE, Burkhard FC, Schumacher M, Kessler TM, Thoeny H, Fleischmann A, *et al.* Twenty years experience with an ileal orthotopic low pressure bladder substitute: lessons to be learned. *J Urol* 2006; **176**:161-6.
16. Steven K, Poulsen AL. The orthotopic Kock ileal neo-bladder: functional results, urodynamic features, complications and survival in 166 men. *J Urol* 2000; **164**:288-95.
17. Stimson CJ, Chang SS, Barocas DA, Humphrey JE, Patel SG, Clark PE, *et al.* Early and late perioperative outcomes following radical cystectomy: 90-day readmissions, morbidity and mortality in a contemporary series. *J Urol* 2010; **184**:1296-300.
18. Novotny V, Hakenberg OW, Wiessner D, Heberling U, Litz RJ, Oehlschlaeger S, *et al.* Perioperative complications of radical cystectomy in a contemporary series. *Eur Urol* 2007; **51**: 397-401.
19. Verleyen P, Billiet I, Mattelaer J, Hardeman M, Werbrouck P. Cystectomy and orthotopic ileal neo-bladder construction. Evaluation of continence and complications in a regional hospital. *Urol Int* 2003; **71**:255-61.
20. Jensen JB, Lundbeck F, Jensen KM. Complications and neo-bladder function of the Hautmann orthotopic ileal neo-bladder. *BJU Int* 2006; **98**:1289-94.

