



THE AGA KHAN UNIVERSITY

eCommons@AKU

Section of Urology

Department of Surgery

2013

Renal arteriovenous malformation: An unusual cause of recurrent haematuria

Mazhar Ali
Aga Khan University

Wajahat Aziz
Aga Khan University, wajahat.aziz@aku.edu

Farhat Abbas
Aga Khan University, farhat.abbas@aku.edu

Follow this and additional works at: https://ecommons.aku.edu/pakistan_fhs_mc_surg_urol



Part of the [Surgery Commons](#), and the [Urology Commons](#)

Recommended Citation

Ali, M., Aziz, W., Abbas, F. (2013). Renal arteriovenous malformation: An unusual cause of recurrent haematuria. *BMJ Case Reports*, 1-3.

Available at: https://ecommons.aku.edu/pakistan_fhs_mc_surg_urol/23

CASE REPORT

Renal arteriovenous malformation: an unusual cause of recurrent haematuria

Mazhar Ali,¹ Wajahat Aziz,² Farhat Abbas³

¹Department of Surgery, Section Urology, Aga Khan University, Karachi, Pakistan
²Aga Khan University Hospital, Karachi, Pakistan

³Department of Urology, Aga Khan University, Karachi, Pakistan

Correspondence to
 Dr Mazhar Ali Memon,
 mazher.ali@aku.edu

SUMMARY

A 54-year-old woman presented with gross painless haematuria. Initial workup showed no abnormality except mild hydronephrosis on CT scan. Cystoscopy and retrograde pyelography did not find any gross lesion and her urine cytology was also negative. She had recurrent haematuria so her CT was reviewed with the radiologist with clinical suspicion of arteriovenous malformation (AVM) which was suggested by relatively increased contrast density in the hemiazygous vein and renal vein in the arterial phase. She underwent angioembolisation of left renal AVM after which her haematuria settled.

BACKGROUND

Renal arteriovenous malformation (AVM) is an unusual cause of recurrent gross haematuria. It may not be picked up on initial imaging studies and endoscopy. A high index of suspicion and the absence of positive findings led to its diagnosis.

CASE PRESENTATION

A 54-year-old hypertensive woman presented to the emergency department with 2 days history of gross painless haematuria leading to clot retention. Bladder wash and catheterisation was performed outside our institute. Her baseline laboratory workup was unremarkable including urine analysis and urine culture. CT abdomen and pelvis with contrast showed left side hydronephrosis and hydroureter without any obstructing lesion. To rule out the possibility of bladder growth, she underwent cystoscopy and left retrograde pyelography. Cystoscopy was essentially unremarkable with no gross lesion in the urinary bladder and no lateralising haematuria. Urine specimen was taken for cytology from the bladder. An open-ended ureteric catheter was placed in the left ureter and another specimen was taken for cytology from the left pelvicalyceal system considering left-sided hydronephrosis and hydroureter on CT scan. Left retrograde pyelography was also performed after taking the cytology specimen which did not reveal any filling defect with prompt clearance of contrast.

Ten days after cystoscopy and biopsy, she again presented to the emergency department with gross painless haematuria, this time with mild left lumbar discomfort, leading to clot retention. The patient was catheterised again and irrigation started.

INVESTIGATIONS

She had a normal clotting profile.

Urine cytology from the bladder and the left ureter were negative for malignancy.

DIFFERENTIAL DIAGNOSIS

Considering gross recurrent haematuria with negative cytology and endoscopy findings, possibilities included a low-grade upper tract transitional cell carcinoma not picked up by cytology and CT scan and renal AVM.

CT scan was reviewed with the radiologist. On second look with the clinical suspicion of AVM in mind, increased contrast density in the left renal vein and the hemiazygous vein draining into the left renal vein were noted (figure 1). This reinforced the clinical suspicion enough to proceed for formal angiography and embolisation.

TREATMENT

She underwent left renal angiography. An arteriovenous malformation was identified near the lower pole of the left kidney supplied by multiple feeders (figure 2A) which were cannulated with a microcatheter and embolised with polyvinyl alcohol particles and coils. However, a tiny branch towards the lower pole supplying a minimal portion of AVM could not be selectively catheterised and embolised. This tortuous vessel (figure 2B) was originating at a right angle from a branch of the lower pole vessel and could not be selectively cannulated with the angiography catheter. Embolisation of the main lower pole vessel or its branch would have led to a large area of renal infarction so it was left alone.

OUTCOME AND FOLLOW-UP

Postangioembolisation the patient remained stable. Her haematuria settled within 24 h of the

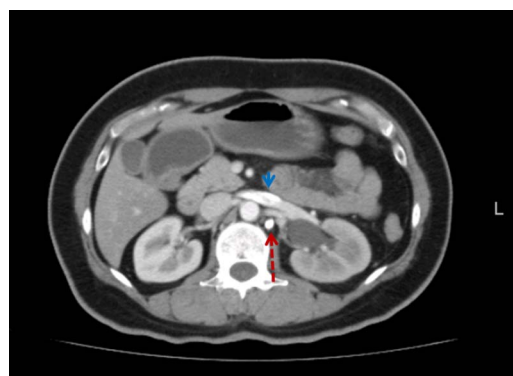

Figure 1 CT scan axial view showing increased contrast density in the hemiazygous (broken arrow) and renal vein (small arrow).

To cite: Ali M, Aziz W, Abbas F. *BMJ Case Rep* Published online: [please include Day Month Year] doi:10.1136/bcr-2013-010374

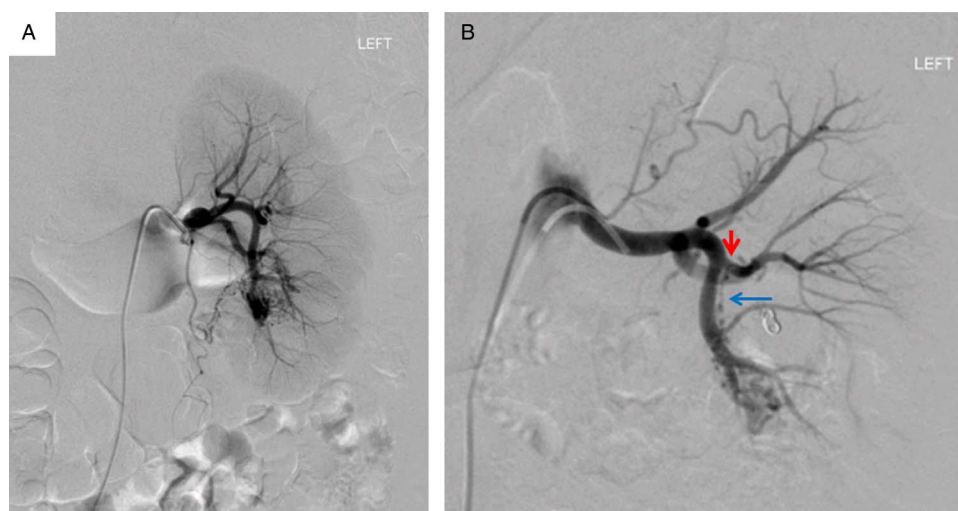


Figure 2 Angiographic image showing (A) contrast pooling at the site of arteriovenous malformation and (B) after coil placement: showing residual tortuous feeding vessel from the lower pole (long blue arrow) and the main trunk from which it is arising at a right angle (small red arrow).

procedure. Currently she is doing well with no more episodes of haematuria at 9 months follow-up. She may need a repeat angiography and embolisation in case of significant rebleeding.

DISCUSSION

Renal AVMs are abnormal communication between arteries and veins. These tortuous vessels lie underneath urothelium that leads to haematuria.¹ The prevalence of renal AVMs is 0.04%. Despite its relatively low-reported prevalence, actual prevalence might be higher as many of patients have no symptoms of the disease.² Renal AVM usually presents in late adult life.¹⁻³ Renal AVMs are classified into two main categories. Congenital renal AVMs that accounts for less than 25% of all renal AVMs.⁴ The other type is acquired or idiopathic lesion that accounts for 75% of all renal AVMs. Acquired or idiopathic lesions results in increased venous return that ultimately effects cardiovascular system and ultimately lead to systolic hypertension and it usually present after the fourth decade of life.⁵ Cystoscopy is needed to rule out any urinary bladder pathology.¹ Ultrasound Doppler is considered to be first imaging study useful in patients with AVM. Its advantage is of being low cost and less invasive in nature.⁶ Multidetector CT scan is one of the most important tool to detect renal AVMs and fistula.⁷ Management of renal AVM depends on signs and symptoms and cause of it. Congenital AVM most of the time remains asymptomatic throughout life and closes spontaneously. Definitive treatment is required in patients who have symptomatic AVM. Patients with persistent haematuria, massive haematuria or frank AVM rupture require therapeutic intervention.⁸⁻⁹ As in our study the patient had persistent frank haematuria so we decided to undergo embolisation of the vessel. In the past few years, a common method of renal AVMs treatment includes partial or total nephrectomy or arterial reconstructive surgeries. With recent advances, transcatheter angiographic embolisation is gaining wide acceptance for the treatment of symptomatic renal AVMs.¹ This procedure is effective at most of the time and safe. It can be performed to avoid surgical exploration.

Learning points

- ▶ Arteriovenous malformation is an unusual cause of haematuria which may lead to significant haemorrhage.
- ▶ Imaging, cytology and endoscopic findings may be normal in such case.
- ▶ A high index of suspicion and the absence of positive findings indicates the diagnosis.
- ▶ Angiographic embolisation provides prompt cessation of active bleeding and may avoid the need for open exploration.

Acknowledgements Dr Sunil Sadruddin Samnani is acknowledged for his contribution with literature search.

Contributors MA and WA wrote the manuscript and also did the literature search FA is the consultant urologist who managed the patient and was responsible for clinical decision-making.

Competing interests None.

Patient consent Obtained.

Provenance and peer review Not commissioned; externally peer reviewed.

REFERENCES

- 1 Özbülbul Nİ, Tola M, Yener Ö. Congenital renal arteriovenous malformation: diagnosis with MDCT angiography. *Ankara Üniversitesi Tıp Fakültesi Mecmuası* 2009;62:65–7.
- 2 Nawa S, Ikeda E, Naito M, *et al.* Idiopathic renal arteriovenous fistula demonstrating a huge aneurysm with a high risk of rupture: report of a case. *Surg Today* 1998;28:1300–3.
- 3 Pande S, Shetty D, Pawar A. Successful treatment with therapeutic embolization of left renal arteriovenous malformation in a haemophilia patient. *Indian J Radiol Imaging* 2002;12:253.
- 4 Muraoka N, Sakai T, Kimura H, *et al.* Rare causes of hematuria associated with various vascular diseases involving the upper urinary tract. *Radiographics* 2008;28:855–67.
- 5 Chauvapun JP, Caty MG, Harris LM. Renal arteriovenous aneurysm in a 4-year-old patient. *J Vasc Surg* 2005;41:535–8.
- 6 Naganuma H, Ishida H, Konno K, *et al.* Renal arteriovenous malformation: sonographic findings. *Abdom Imaging* 2001;26:0661–3.
- 7 Helenon O, Correas J-M, Chabriaux J, *et al.* Renal vascular Doppler imaging: clinical benefits of power mode. *Radiographics* 1998;18:1441–54.

- 8 An H-S, Kang T-G, Yun H-J, *et al.* Hypertension caused by renal arteriovenous fistula. *Korean Cir J* 2009;39:548–50.
- 9 Beaujeux R, Saussine C, Al-Fakir A, *et al.* Superselective endo-vascular treatment of renal vascular lesions. *J Urol* 1995;153:14–17.

Copyright 2013 BMJ Publishing Group. All rights reserved. For permission to reuse any of this content visit <http://group.bmj.com/group/rights-licensing/permissions>.
BMJ Case Report Fellows may re-use this article for personal use and teaching without any further permission.

Become a Fellow of BMJ Case Reports today and you can:

- ▶ Submit as many cases as you like
- ▶ Enjoy fast sympathetic peer review and rapid publication of accepted articles
- ▶ Access all the published articles
- ▶ Re-use any of the published material for personal use and teaching without further permission

For information on Institutional Fellowships contact consortiasales@bmjgroup.com

Visit casereports.bmj.com for more articles like this and to become a Fellow