



THE AGA KHAN UNIVERSITY

eCommons@AKU

---

Section of Urology

Department of Surgery

---

2013

## An unusual combination of extra-adrenal pheochromocytoma and arteriovenous malformation of the ureter in a young adult

Ali Khawaja  
*Aga Khan University*

Wajahat Aziz  
*Aga Khan University, wajahat.aziz@aku.edu*

Syed Muhammad Nazim  
*Aga Khan University, muhammad.nazim@aku.edu*

Farhat Abbas  
*Aga Khan University, farhat.abbas@aku.edu*

Follow this and additional works at: [https://ecommons.aku.edu/pakistan\\_fhs\\_mc\\_surg\\_urol](https://ecommons.aku.edu/pakistan_fhs_mc_surg_urol)



Part of the [Surgery Commons](#), and the [Urology Commons](#)

---

### Recommended Citation

Khawaja, A., Aziz, W., Nazim, S. M., Abbas, F. (2013). An unusual combination of extra-adrenal pheochromocytoma and arteriovenous malformation of the ureter in a young adult. *BMJ Case Reports*, 1-4.

Available at: [https://ecommons.aku.edu/pakistan\\_fhs\\_mc\\_surg\\_urol/22](https://ecommons.aku.edu/pakistan_fhs_mc_surg_urol/22)

## CASE REPORT

# An unusual combination of extra-adrenal pheochromocytoma and arteriovenous malformation of the ureter in a young adult

Ali Khawaja,<sup>1</sup> Wajahat Aziz,<sup>2</sup> Syed Muhammad Nazim,<sup>2</sup> Farhat Abbas<sup>2</sup>

<sup>1</sup>Medical College, The Aga Khan University Hospital, Karachi, Sindh, Pakistan  
<sup>2</sup>Department of Surgery, Section of Urology, The Aga Khan University Hospital, Karachi, Sindh, Pakistan

**Correspondence to**  
 Dr Wajahat aziz,  
 wajahat.aziz@aku.edu

## SUMMARY

We present a case of a 24-year-old gentleman who presented with painless pan haematuria for 2 weeks. During the workup, he was diagnosed to have a retrocaval mass after a CT scan while cystoscopy revealed a polypoidal pulsating lesion in the left ureter. After surgical manipulation of the retrocaval mass, the blood pressure of the patient raised to 260/130 mm Hg. It was completely resected and diagnosed as extra-adrenal pheochromocytoma (paraganglioma) after histopathology. The lesion in the ureter was completely excised and fulgurated and diagnosed as an arteriovenous malformation. To the best of our knowledge, this is the first patient to be presented in the literature with this unusual combination.

## BACKGROUND

Extra-adrenal pheochromocytomas (EAPs), also known as paragangliomas are tumours that arise from the chromaffin tissue complexes of the neuroendocrine system. They may arise from any part of the sympathetic chain, extending from the base of the brain to the urinary bladder.<sup>1</sup> Contradictory to the conventional teaching of the '10% rule' of pheochromocytomas according to which 10% of pheochromocytomas are extra-adrenal, it is now suggested that EAPs comprise 15% and 30% of adult and paediatric pheochromocytomas, respectively.<sup>1</sup>

Arteriovenous malformation (AVM) of the genitourinary tract is rarely encountered and most are confined to renal AVM. To the best of our knowledge, only three cases have been reported of ureteric AVM in the English literature.<sup>2-4</sup>

We report a case of a young man who presented with an unusual combination of ureteric AVM and an asymptomatic EAP.

## CASE PRESENTATION

A 24-year-old gentleman with no known comorbidity presented with gross, painless pan haematuria for 2 weeks with occasional passage of amorphous and vermiform clots. There was no history of flank pain, lower urinary tract symptoms and fever. His medical history was unremarkable. The patient's mother had undergone nephrectomy for renal cell carcinoma.

## INVESTIGATIONS

His basic biochemistry, urine analysis and culture were unremarkable as was the ultrasound abdomen. He had a cystoscopy outside our institute which

showed left lateralising haematuria without any lesion in the bladder.

CT scan was performed which revealed multilobulated retrocaval mass at the level of renal veins. The mass was located posterior to inferior vena cava (IVC) measuring 2.9×2.9 cm in the short-axis diameter. It was pushing the IVC anteriorly narrowing its lumen with superior displacement of the right renal vein and lying at some distance from the renal pelvis. CT scan did not show any regional or distant lymphadenopathy. Considering the retroperitoneal mass in a young man, ultrasound scrotum and tumour markers for germ cell tumours were performed which were within normal limits.

The patient underwent a CT-guided biopsy of the retrocaval mass which revealed a cellular neoplastic lesion composed of back-to-back aggregates of neoplastic cells. The immunohistochemical staining was negative for Cytokeratin AE1/AE3, Cytokeratin CAM 5.2, CD 31, CD 34, HMB-45 and Synaptophysin, Hep-par1; equivocal for CD10 and positive for Vimentin and S-100.

He was planned for cystoscopy, left ureterorenoscopy for left lateralising haematuria and exploration of the retroperitoneal mass. Considering the position adjacent to major renal vessels, MRI with angiography was performed which showed the lesion to be in between renal artery and renal vein and away from the collecting system. It appeared hypointense on T1-weighted sequences, slightly hyperintense on T2-weighted sequences and showed intense enhancement on postcontrast sequences. It had slightly increased in size to 3.1 cm in anteroposterior and 3.7 cm in transverse dimension as compared to the previous CT scan (figure 1). Both kidneys and renal arteries appeared unremarkable.

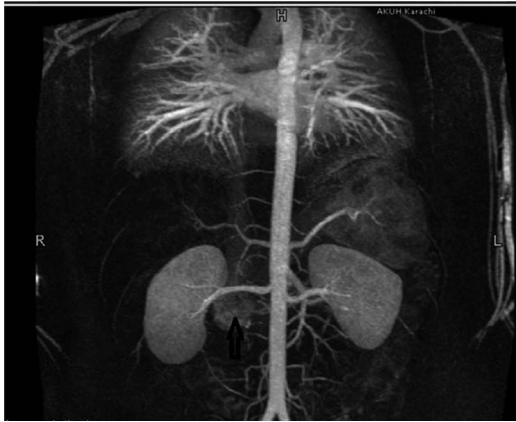## DIFFERENTIAL DIAGNOSIS

Considering the lateralising haematuria and retroperitoneal mass, we considered the diagnosis of upper tract transitional cell carcinoma with lymph node metastasis. Family history of renal cell carcinoma was also curious but in the absence of visible renal lesion in this young man renal cell carcinoma was unlikely. Germ cell tumour with retroperitoneal metastasis was excluded with clinical examination and scrotal ultrasound supplemented with tumour markers. Still extragonadal germ cell tumour was a possibility.

So the differential diagnosis included:

1. Upper tract transitional cell carcinoma;

**To cite:** Khawaja A, Aziz W, Nazim SM, et al. *BMJ Case Rep* Published online: [please include Day Month Year] doi:10.1136/bcr-2013-009491



**Figure 1** Magnetic resonance angiography showing the retrocaval mass (arrow).

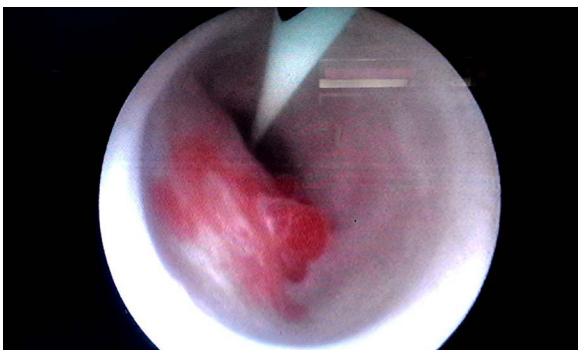
2. Occult renal cell carcinoma with lymph node metastasis;
3. Extragonadal germ cell tumour;
4. Retroperitoneal sarcoma.

The last two did not explain the lateralising haematuria in the absence of overt involvement of urinary tract.

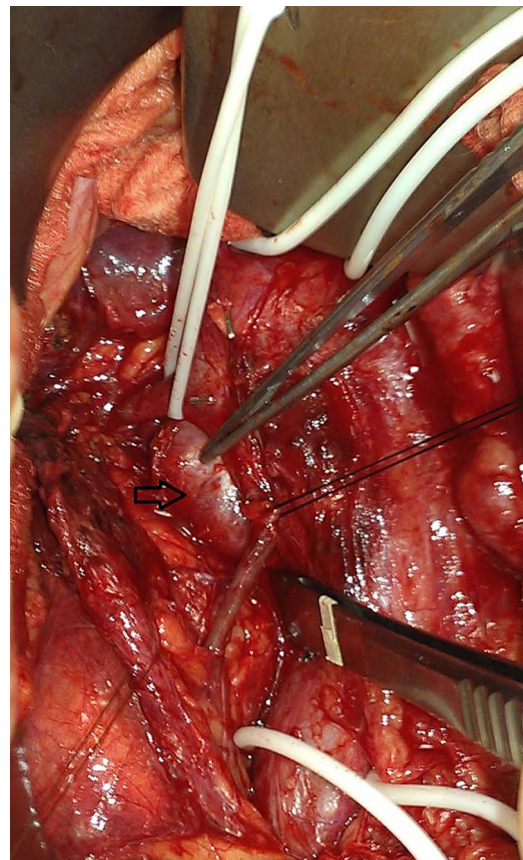
#### TREATMENT

Cystoscopy was unremarkable. Bilateral ureteric jets were clear. Left ureterorenoscopy revealed a single 2–3 cm polypoidal pulsating lesion on the medial wall of the ureter at the upper border of sacroiliac joint (figure 2). Biopsy was taken which resulted in flattening of the lesion after bleeding from the biopsy site. It subsequently refilled with blood resulting in reappearance of the lesion and a provisional diagnosis of AVM was made. Biopsy of the lesion was performed and sent for frozen section analysis which reported it to be benign urothelial mucosa and fibrocollagenous tissue with haemorrhage. The lesion was completely excised, the base was fulgurated and a 6 Fr JJ ureteric stent was placed. Histopathological analysis revealed scanty fragment of fibrocollagenous tissue, multiple blood vessels and focal epithelial lining confirming the diagnosis of AVM.

Abdomen was then opened via a midline incision. Duodenum was Kocherised and a 4×4 cm retrocaval well-encapsulated tumour was located (figure 3). Blood pressure increased to 260/130 mm Hg on manipulation of retrocaval tumour and a provisional diagnosis of EAP (paraganglioma) was made. Proximal and distal control of IVC, both renal veins and right gonadal vein were obtained. The mass was resected from behind IVC and sent for histopathological analysis which showed a



**Figure 2** Polypoidal lesion found during left ureteroscopy.

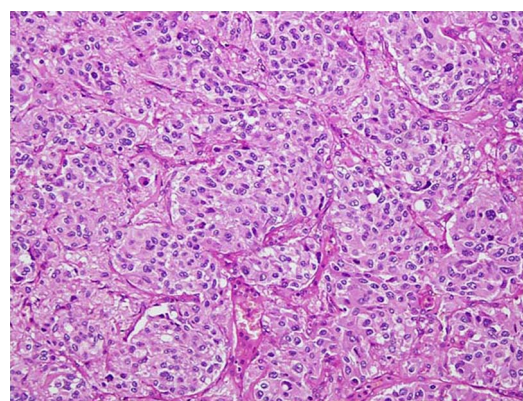


**Figure 3** Operative view showing the retrocaval paraganglioma (arrow).

neoplastic lesion composed of nests of cells with abundant eosinophilic (pink) cytoplasm confirming the diagnosis of EAP (figure 4). Immunohistochemical staining showed positivity for synaptophysin, chromogranin-A and vimentin while it was negative for cytokeratin AE1/AE3 and cytokeratin CAM 5.2 and equivocal for melan-A.

#### OUTCOME AND FOLLOW-UP

The patient recovered well postoperatively without any complications and was discharged on sixth postoperative day. Double J stent was removed with flexible cystoscope after 4 weeks. On 4 months of follow-up in the clinic, the patient is free of haematuria and other complications.



**Figure 4** Section showing nests of tumour cells with central uniform nuclei and abundant pink cytoplasm. H&E×20.

## DISCUSSION

Pheochromocytoma is a rare entity, constituting 0.1–1% of the patients with hypertension.<sup>5 6</sup> Majority (75%) of the cases are sporadic in which the classical ‘rule of 10s’ applies with 10% being bilateral, 10% malignant and 10% extra-adrenal while the remaining familial cases are most often associated with multiple endocrine neoplasia 2A and 2B syndromes, neurofibromatosis and Von-Hippel-Lindau syndrome.<sup>7</sup> EAP or paragangliomas, hence are even rarer and can occur anywhere along the sympathetic chain distributed along the para-vertebral and para-aortic axes with the organ of Zuckerkandl being the most common site of involvement. Paragangliomas are the dominant source of catecholamines in the fetal life. However, failure to regress after the normal age of 3 years results in the occurrence of paragangliomas at those sites.<sup>1</sup> Paragangliomas are now considered to constitute a higher percentage of pheochromocytomas rather than the 10% thought conventionally.<sup>1</sup> Moreover, these are more multicentric and have a higher potential for malignancy as compared to the adrenal tumours.<sup>8</sup>

Patients usually present with the classical symptoms of headache, sweating, palpitations, tremors and hypertension mostly due to the uncontrolled release of catecholamines from these functional tumours. Moreover, paragangliomas can be brought into consideration because of the symptoms resulting from the mass effect leading to compression of the adjacent structures which may lead to ureteric obstruction, small bowel obstruction or renal artery stenosis<sup>9–11</sup> However, some of the patients can be completely asymptomatic and a high index of suspicion is required to reach a correct diagnosis. Considering the location of the tumour, patients can be misdiagnosed to have some other conditions including parathyroid adenoma and pituitary microadenoma.<sup>12 13</sup> In this patient, an incidental finding of a retrocaval mass was observed and a decision to resect it was made by the primary team. Though the mass was in close proximity to IVC, no definite obstruction was seen. Intraoperatively, manipulation of the mass resulted in a sudden rise of the blood pressure and the diagnosis of a paraganglioma was confirmed after the histopathological analysis.

In symptomatic patients, initial diagnostic investigations include demonstration of catecholamines and/or its metabolites in plasma or urine. Imaging then subsequently plays an important role in localising the adrenal and EAPs. CT scan is usually the initial modality of choice for detecting these tumours. If the mass is not localised on CT scan and the disease is clinically or biochemically suspected, MRI is then indicated. Functional imaging can also be performed to confirm the presence of EAPs. The most commonly studied functional imaging is <sup>131</sup>I-labelled metaiodobenzylguanidine (<sup>131</sup>I-MIBG) which shows high sensitivity and specificity in detecting EAPs. It can also be used to assess multifocality, metastasis and recurrence of the tumour.<sup>1</sup> In our patient, plasma and urinary catecholamines were within normal limits while <sup>131</sup>I-MIBG was not performed due to the patient being asymptomatic and to low index of suspicion. The retrocaval mass was identified after a CT scan but since it was in close proximity to IVC and renal vein, magnetic resonance angiography was also performed to rule out invasion of these major vessels. If the patient is symptomatic and in hypertensive crisis, stabilisation of the symptoms with medical intervention is essential before proceeding to surgical resection. Since this patient was asymptomatic, an elective resection of the mass was performed which is the definite treatment of EAPs.

Congenital arteriovenous malformations of the urinary tract are extremely rare with majority of them being limited to kidney and bladder. Patients usually present with the complaints

of haematuria and discomfort in the lumbar region. To the best of our knowledge, only three cases of ureteric AVM have been reported in the past. Kaplan *et al*<sup>2</sup> reported a case of a 34-year-old woman with a 1 cm polypoidal AVM in the left ureter, Sech *et al*<sup>3</sup> reported a 29-year-old woman with a 12 cm polypoidal AVM in the right ureter while Tang *et al*<sup>4</sup> presented the case of a 19-year-old girl with right ureteric AVM. Kaplan *et al* and Sech *et al* used endoscopic resection of the lesion and fulguration (as in our patient) while Tang *et al* used selective embolisation to manage the patient. All the patients remained free of complications and recurrence on follow up. In this patient, haematuria was the primary complaint while the retrocaval paraganglioma was diagnosed incidentally during the workup for haematuria caused by ureteric AVM.

## Learning points

- ▶ Rare causes of haematuria, like arteriovenous malformation, should be considered in young patients with lateralising haematuria with no gross lesion in the urinary tract after imaging.
- ▶ Arteriovenous malformation of the ureter can be managed with endoscopic resection and fulguration.
- ▶ A high index of suspicion is required to diagnose non-functional extra-adrenal pheochromocytomas.
- ▶ Resection of the extra-adrenal pheochromocytomas is the definite mode of treatment.

**Contributors** MNS was involved in the conception and design of the article. AK contributed by preparing the draft and writing the article. WA and FA reviewed and edited the article. All the authors reviewed the final draft of the manuscript.

**Competing interests** None.

**Patient consent** Obtained.

**Provenance and peer review** Not commissioned; externally peer reviewed.

## REFERENCES

- 1 Disick GI, Palese MA. Extra-adrenal pheochromocytoma: diagnosis and management. *Curr Urol Rep* 2007;8:83–8.
- 2 Kaplan SA, Brown W, Bixon R, *et al*. Arteriovenous malformation of ureter. *Urology* 1992;40:450–2.
- 3 Sech SM, Saboorian MH, Ashfaq R, *et al*. Polypoid arteriovenous malformation of the ureter. *J Urol* 1997;158:1903–4.
- 4 Tang CN, Law IC, Lu PP, *et al*. Arteriovenous malformation of the ureter—a rare cause of hematuria. *Br J Urol* 1997;80:500–1.
- 5 Anderson GH Jr, Blakeman N, Streeten DH. The effect of age on prevalence of secondary forms of hypertension in 4429 consecutively referred patients. *J Hypertens* 1994;12:609–15.
- 6 Omura M, Saito J, Yamaguchi K, *et al*. Prospective study on the prevalence of secondary hypertension among hypertensive patients visiting a general outpatient clinic in Japan. *Hypertens Res* 2004;27:193–202.
- 7 Abdullah I, Cossey K, Jeanmonod RK. Extra-adrenal pheochromocytoma in an adolescent. *West J Emerg Med* 2011;12:258–61.
- 8 O’Riordain DS, Young WF Jr, Grant CS, *et al*. Clinical spectrum and outcome of functional extraadrenal paraganglionoma. *World J Surg* 1996;20:916–21.
- 9 Whalen RK, Althausen AF, Daniels GH. Extra-adrenal pheochromocytoma. *J Urol* 1993;147:1–10.
- 10 Yadav S, Singh SK, Sharma SK, *et al*. Extra-adrenal pheochromocytoma: a cause of ureteral obstruction. *J Urol* 2000;163:264.
- 11 Blecha M, Galanopolous C, Dharkar D, *et al*. Massive organ of Zuckerkandl inducing small bowel obstruction. *J Am Coll Surg* 2005;201:480–1.
- 12 Sinha S, Sharma MC, Sharma BS. Malignant paraganglioma of the sellar region mimicking a pituitary macroadenoma. *J Clin Neurosci* 2008;15:937–9.
- 13 Bhattacharya A, Mittal BR, Bhansali A, *et al*. Cervical paraganglioma mimicking a parathyroid adenoma on Tc-99m sestamibi scintigraphy. *Clin Nucl Med* 2006;31:234–6.

Copyright 2013 BMJ Publishing Group. All rights reserved. For permission to reuse any of this content visit <http://group.bmj.com/group/rights-licensing/permissions>.  
BMJ Case Report Fellows may re-use this article for personal use and teaching without any further permission.

Become a Fellow of BMJ Case Reports today and you can:

- ▶ Submit as many cases as you like
- ▶ Enjoy fast sympathetic peer review and rapid publication of accepted articles
- ▶ Access all the published articles
- ▶ Re-use any of the published material for personal use and teaching without further permission

For information on Institutional Fellowships contact [consortiasales@bmjgroup.com](mailto:consortiasales@bmjgroup.com)

Visit [casereports.bmj.com](http://casereports.bmj.com) for more articles like this and to become a Fellow