



THE AGA KHAN UNIVERSITY

eCommons@AKU

Section of Cardiothoracic Surgery

Department of Surgery

January 2009

Kawashima operation: functional modification of bidirectional Glen shunt with left superior vena cava in single ventricular morphology

Syed Shahabuddin
Aga Khan University

Saulat Fatimi
Aga Khan University

Mehnaz Atiq
Aga Khan University

Muneer Amanullah
Aga Khan University

Follow this and additional works at: http://ecommons.aku.edu/pakistan_fhs_mc_surg_cardiothoracic



Part of the [Surgery Commons](#)

Recommended Citation

Shahabuddin, S., Fatimi, S., Atiq, M., Amanullah, M. (2009). Kawashima operation: functional modification of bidirectional Glen shunt with left superior vena cava in single ventricular morphology. *Journal of the Pakistan Medical Association*, 59(1), 43-5.

Available at: http://ecommons.aku.edu/pakistan_fhs_mc_surg_cardiothoracic/22

Kawashima operation: Functional modification of Bidirectional Glenn shunt with left superior vena cava in single ventricular morphology

Syed Shahabuddin, Saulat Fatimi, Mehnaz Atiq, Muneer Amanullah

Division of Congenital Cardiac Surgery, Department of Surgery, The Aga Khan University Hospital, Karachi.

Abstract

Single ventricle physiology offers limited options with significant morbidity and mortality. The Glenn shunt is a mid-stage procedure for the Fontan circulation. With persistent left Superior Vena Cava (SVC) and Azygos continuation of the Inferior Vena Cava (IVC) to the SVC, needs the development of bilateral bidirectional Glenn shunts. Fifteen patients underwent Bidirectional Glenn shunt procedure over a period of ten years. Of these two were

found to have left SVC along with interrupted IVC and its Azygos continuation to the SVC. These two patients underwent the Kawashima operation.

A seven years old girl was admitted via emergency with severe cyanosis. She had tricuspid atresia, azygos continuation of IVC with single ventricle physiology. She had a complicated postoperative course with prolonged hospital stay after bilateral bidirectional Glenn shunt (Kawashima operation). She successfully has completed

Fontan after 5 years. The second case of a 7 year old girl had elective surgery for DORV (double outlet right ventricle), pulmonary atresia and azygos continuation of IVC and persistent left SVC. She had an uneventful postoperative course.

The Kawashima operation is an established surgical procedure to deal with bilateral SVCs. The procedure is safe; outcome is favourable and prepares the patient for total cavo-pulmonary shunt.

Introduction

Single ventricular physiology is associated with a shorter life expectancy. It includes variety of complex congenital heart diseases where only one ventricle is responsible for supporting both systemic and pulmonary circulation. However some of the anatomical biventricular hearts require to be managed on principles of single ventricle.

The role of Bidirectional Glen (superior vena cava to pulmonary artery) shunt has been well established as an intermediate palliation in patients with single ventricular physiology.¹ We have already established the safety of bidirectional Glen shunt in a single ventricle.² The management of such patients is even more challenging for congenital cardiac surgeons in presence of bilateral SVC's. Two children underwent bilateral bidirectional cavo pulmonary shunt operation for tricuspid atresia and a variant of double outlet right ventricle. The first child underwent salvage bilateral bidirectional Glen shunt with expected stormy postoperative course. The second child had an elective uneventful surgery. These children had bilateral superior vena cavae, interrupted inferior vena cava with Azygos continuation of IVC. This modified bilateral bidirectional Glen shunt is also known as the Kawashima operation.³ We describe our surgical strategy in two cases with presence of left superior vena cava and azygos continuation of the IVC in patients with a single ventricular morphology.

Case-1

A seven year old girl was diagnosed to have Tricuspid Atresia with Ventricular Septal Defect (VSD), pulmonary stenosis, Azygos continuation of IVC, and a single ventricle physiology. She had a modified Blalock Taussig (BT) shunt, that is, subclavian artery to pulmonary artery in infancy. She presented with progressively increasing cyanosis and failure to thrive. She was advised surgical intervention abroad. On her way to the airport she became unwell and was brought to the emergency, room of Aga Khan Hospital with severe cyanosis. While she was being wheeled to the operating room for a BT shunt operation, she had a cardiopulmonary arrest necessitating

cardiopulmonary resuscitation (CPR). While CPR was being performed, cardiopulmonary bypass (CPB) was established. This was done with aortic and right atrial venous cannulae after full systemic heparinization (300U/Kg). Instead of a BT shunt a bilateral Glen shunt (BDG) was thought to be more beneficial. In the presence of bilateral SVC's three venous cannulae were used. The right and left SVC's were divided at their junction with atria and anastomosed to right and left pulmonary artery respectively Fig-1a & 1b. She was weaned off cardiopulmonary support

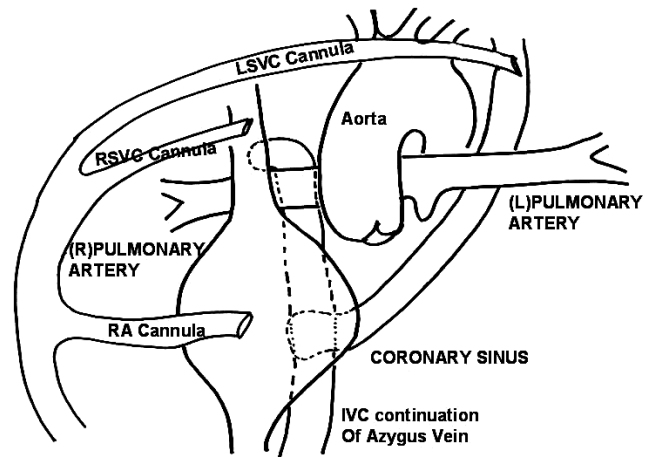


Figure 1a: Line diagram to show additional (third) left SVC cannula.

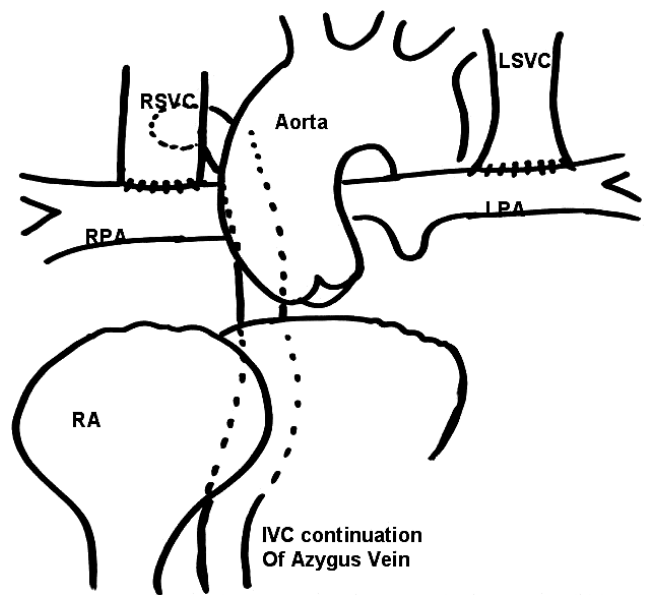


Figure 1b: Line diagram showing bilateral cavopulmonary shunt.

with heavy doses of inotropic support. She had re-exploration of the mediastinum for bleeding and was extubated on first post-operative day. She had a prolonged stay in the Intensive Care Unit (ICU) to optimize cardiac

function, and was discharged on the 17th post-operative day. She did well at follow up and subsequently underwent completion of Fontan operation after 5 years.

Case-2

Another seven years old girl was diagnosed to have DORV, Pulmonary atresia and azygos continuation of IVC into a persistent left SVC. She had presented at birth with cyanosis and underwent construction of a modified BT shunt at four days of age. As she grew older her cyanosis worsened. She was evaluated regarding further surgical intervention and her anatomical lesions were found unsuitable for biventricular repair. It was planned to treat her in line of single ventricle. A decision was made to perform Bidirectional Glenn shunt to improve pulmonary blood flow and prepare her for future Fontan circulation. She underwent elective bilateral bidirectional Glenn shunt on cardiopulmonary bypass. She came off CPB on small dose of inotropes. Her postoperative course was uneventful. She was extubated on first postoperative day and was discharged on 6th post-op day. She has been asymptomatic on follow up. She will be requiring completion of Fontan operation in the future.

Discussion

Fontan in Bordeaux (France) in 1968 performed total cavo-pulmonary shunt by diverting SVC and IVC blood to the pulmonary artery for right heart bypass and has remained of great value in patients with single ventricle physiology.⁴ However, a group of children with univentricular heart are at high risk for Fontan procedure. These children require interim palliation with bidirectional Glenn shunt which in turn prepares these children for completion of Fontan at a later stage. We described two case reports about children with heterotaxy syndrome⁵ having intra-cardiac defects, right and left SVC along with azygos continuation of IVC managed with staged surgical procedure. The majority of patients entering the univentricular heart protocol have to undergo various forms of surgical procedures to balance and optimize pulmonary and systemic blood flow. Initial palliations to increase pulmonary blood flow in the presence of severely reduced pulmonary perfusion include aorto-pulmonary shunt procedures similar to our patients who underwent modified BT shunts in the immediate post-natal period. Subsequently both of them underwent bilateral bidirectional Glenn shunt, facilitating completion of Fontan and one of the patient has

had this procedure and the other patient will be requiring the same in the near future. It is questionable; whether in the presence of IVC continuation of azygos vein, completion of Fontan is necessary? It is important to have completion Fontan, as pulmonary arterio-venous fistula develops and collaterals from SVC and the hepatic veins, drain into the right atrium contributing to substantial cyanosis and hypoxaemia specially with exercise.⁶ The ultimate goal is to off load the systemic ventricle and completely divert the venous return to pulmonary circulation.

In the Indian Sub-continent, severe complex congenital cardiac problems are considered uncorrectable and hence several children are deprived of surgical correction or palliation. Our report of two cases is an effort to provide palliation to such children and make them participate in the society at a better functional level.

To conclude, in patients with this unusual anatomy, the Kawashima operation is safe and associated with good outcome. It also prepares the patient for future Fontan circulation by establishing a near total cavo-pulmonary shunt.

Acknowledgement

We are grateful to Dr. Muneer Amanullah for the line diagrams.

Footnotes

Presented at 6th Biennial International Conference of Pakistan Society of Cardiovascular and Thoracic Surgeons, Karachi, Pakistan, 14 - 17, December, 2006.

References

1. Lamberti JJ, Spicer RL, Waldman JD, Grehl TM, Thomson D, George L, et al. The bidirectional cavopulmonary shunt. *J Thorac Cardiovasc Surg* 1990; 100: 22-30.
2. Khan G, Ali SS, Fatimi SH. Bidirectional cavopulmonary shunt for cyanotic heart diseases: surgical experience from a developing country. *J Pak Med Assoc* 2003 ; 53:506-9.
3. Kawashima Y, Kitamura S, Matsuda H, Shimazaki Y, Nakano S, Hirose H. Total cavopulmonary shunt operation in complex cardiac anomalies: A new operation. *J Thorac Cardiovasc Surg* 1984; 87: 74-81.
4. Anecchino FP, Fontan F, Chauve A, Quaegebeur J. Palliative reconstruction of the right ventricular outflow tract in tricuspid atresia: a report of 5 patients. *Ann Thorac Surg* 1980; 29:317-21
5. Bartram U, Wirbelauer J, Speer CP. Heterotaxy Syndrome - asplenia and polysplenia as indicators of visceral malposition and complex congenital heart disease. *Biol Neonate* 2005; 88:278-90.
6. McElhinney DB, Kreutzer J, Lang P, Mayer JE Jr, del Nido PJ, Lock JE. Incorporation of the hepatic veins into the cavopulmonary circulation in patients with heterotaxy and pulmonary arteriovenous malformations after a Kawashima procedure. *Ann Thorac Surg* 2005; 80: 1597 - 603.