



THE AGA KHAN UNIVERSITY

eCommons@AKU

Section of Dental-Oral Maxillofacial Surgery

Department of Surgery

July 2010

Soft tissue profile response in extraction versus non-extraction orthodontic treatment

Munizeh Khan

Section of Dentistry, Department of Surgery, The Aga Khan University Hospital, Karachi

Mubassar Fida

Section of Dentistry, Department of Surgery, The Aga Khan University Hospital, Karachi

Follow this and additional works at: http://ecommons.aku.edu/pakistan_fhs_mc_surg_dent_oral_maxillofac

 Part of the [Endodontics and Endodontology Commons](#), and the [Surgery Commons](#)

Recommended Citation

Khan, M., Fida, M. (2010). Soft tissue profile response in extraction versus non-extraction orthodontic treatment. *Journal of the College of Physicians and Surgeons Pakistan*, 20(7), 454-459.

Available at: http://ecommons.aku.edu/pakistan_fhs_mc_surg_dent_oral_maxillofac/38

Soft Tissue Profile Response in Extraction Versus Non-Extraction Orthodontic Treatment

Munizeh Khan and Mubassar Fida

ABSTRACT

Objective: To compare changes occurring in the soft tissue profile with orthodontic treatment in extraction versus non-extraction cases, and to determine the hard and soft tissue parameters that show significant correlations to understand the factors influencing the response to tooth movement.

Study Design: Quasi-experimental.

Place and Duration of Study: Dental Section, The Aga Khan University Hospital, Karachi, from 2005 to 2008.

Methodology: Pre- and post-treatment lateral cephalographs of 34 subjects were assessed. For half of the patients (n=17), treatment included the extraction of 4 premolars, whereas the other half were treated by the non-extraction approach. Incisal and soft tissue effects of treatment were analyzed and compared between both groups using the independent sample t-test to assess the degree of change with orthodontic treatment. Pearson's correlation test was used to determine correlation.

Results: The extraction group finished with a statistically significant reduction in upper and lower lip procumbency ($p=0.004$ and 0.021), while the non-extraction group finished with a slight increase in lower lip procumbency ($p=0.009$) due to significant increase in IMPA ($p=0.046$). Although the premolar extraction group showed greater soft tissue changes with treatment, post-treatment comparisons showed that both groups finished within the same soft tissue parameters. Pearson's correlation revealed statistically significant correlations between the upper and lower lips and upper and lower incisors ($p < 0.01$).

Conclusion: The effects of the two types of orthodontic treatment on the facial soft tissues were very similar, indicating that treatment, involving the extraction of premolars, does not have a detrimental effect on facial aesthetics provided the decision to extract is on sound basis and the mechanics are controlled.

Key words: Premolar extractions. Soft tissue profile. Cephalometric analysis. IMPA (Mandibular incisor to mandibular plane angle).

INTRODUCTION

It is generally accepted that orthodontic treatment will have some sort of an effect on the facial proportions. Current trends show a preference for fuller, more prominent lips for a youthful appearance,¹ hence the common belief that premolar extractions can lead to a 'dishing in' of the profile and premature aging of the face challenge the modality of this treatment as being desirable. With the development of different appliances and techniques for molar distalization, non-extraction therapy generally takes precedence. However, certain conditions justify the need for extractions, whereas others may be borderline. The question then arises: can premolar extractions be undertaken without negatively affecting the soft tissue characteristics of the patient?

Proffit indicated that the decline in extraction frequencies over the years occurred due to several factors, including concern regarding facial aesthetics, stability and

temporomandibular dysfunction, as well as changes in technique.² Although the exact frequency of orthodontic extractions are yet unknown due to inter-operator differences,³ almost one-third of all malocclusions are said to be severe enough to warrant the need for extractions.⁴

Facial soft tissues are affected by a variety of variables including skeletal relationships, dental positions and soft tissue thickness and function; however, the exact nature of these relationships is still debatable. Literature reveals that the extraction of 4 premolars generally tends to flatten the profile by 2-3 mm when compared with non-extraction treatment.⁵ However, many authors believe that undesirable facial aesthetics at the end of orthodontic treatment cannot be attributed to the extraction of premolars, with proper case selection and management being the clinician's responsibility.⁶⁻⁸ Although the Pakistani literature has studied the skeletal as well as dental arch changes with treatment,⁹ no local research on the soft tissue response to extraction versus non-extraction orthodontic treatment currently exists.

With reference to the hard to soft tissue relationship, different investigators have reported diverging views. Whereas some studies have aimed to predict the soft tissue response to tooth movement,¹⁰ others maintain that no good predictors of the precise response have

Department of Surgery, The Aga Khan University Hospital, Karachi-74800.

Correspondence: Dr. Mubassar Fida, Assistant Professor Orthodontics, Section of Dentistry, Department of Surgery, The Aga Khan University Hospital, Stadium Road, Karachi.
E-mail: mubassar.fida@aku.edu

Received December 31, 2008; accepted April 19, 2010.

been identified.¹¹ This complicates the picture for the orthodontist, for whom the simple concept of a passive drape of the soft tissues over the underlying hard tissues would have made changes easily foreseeable.

The purpose of the present study was to compare the changes occurring in the soft tissue profile in response to orthodontic treatment in extraction versus non-extraction cases, and to determine the parameters among the hard and soft tissue variables that show significant correlations to better understand the factors influencing the response to tooth movement.

METHODOLOGY

This was a quasi-experimental study conducted from 2005 to 2008 at the Dental Section, the Aga Khan University Hospital, Karachi. The lateral cephalometric records at two time periods (pre-treatment, T_0 and end of active treatment, T_1) of 34 patients having undergone routine orthodontic treatment were selected on the basis of the treatment modality provided and availability of records of adequate diagnostic quality. Patients who presented with severe craniofacial anomalies, need for surgical or orthopedic intervention or with history of previously extracted or missing teeth were excluded from the study. All patients were treated by the same orthodontist with comprehensive fixed appliance mechanotherapy.

Two groups of 17 patients each (13 females, 4 males) were formed, namely, the extraction group involving 4 premolar extractions, and the non-extraction group. Based on cephalometric analysis, all patients presented with either Angle's Class I ($n=24$) or Class II malocclusion ($n=10$).

Each pair of pre and post-treatment lateral cephalographs was hand-traced on standard acetate paper at the same sitting to minimize tracing error. Cephalometric landmarks, reference lines, linear and angular measurements used in the study are depicted in Figure 1. A horizontal reference line (HRL) was constructed 7° inferior to the sella-nasion plane, from which a perpendicular was dropped through sella. This vertical reference line, called the sella-perpendicular (SP), was used to assess the sagittal incisal as well as soft tissue positions (Annexure 1B).

The data were analyzed using SPSS for Windows (version 14.0, SPSS Inc. Chicago) where pre and post-treatment differences amongst the extraction and non-extraction groups respectively were calculated by employing the paired sample t-test. Comparison of pre and post-treatment differences between extraction and non-extraction groups were performed using the independent sample t-test. Pearson's correlation coefficients and associated levels of significance were

calculated to investigate for significant correlations among the variables. P-value of less than 0.05 was taken as statistically significant. To evaluate measurement error, 10 randomly selected cephalographs were retraced and measured one month after the initial procedure. Paired t-test was used to evaluate intra-examiner reliability.

RESULTS

The mean age of the extraction patients was 14 years and 6 months at the start of treatment, while that of the non-extraction patients was 14 years and 8 months. The mean treatment time for the extraction group was 2 years and 7 months, where as it was 2 years and 1 month for the non-extraction group.

The significant differences amongst the pre-treatment morphological characteristics were seen in the dental and soft tissue relationships, with significantly greater tooth size-arch length discrepancy in the mandibular arch ($p=0.018$) and a more procumbent lower lip ($p=0.016$) in the group that was treated with premolar extractions.

The results for intra-examiner reliability showed no significant differences between the two sets of measurements ($p\text{-value}=0.548$).

Significant changes were observed in the hard as well as soft tissue characteristics in the group of patients subjected to all 4 premolar extractions (Table I). These changes included a reduction in the angle SNA (sella to nasion to point A angle, Annexure 1A) by a mean of 2° , $p < 0.001$) and upper and lower incisor retraction (mean 5.12 mm, $p < 0.001$ and 2.88 mm, $p=0.001$ respectively), thereby resulting in a decrease in lip prominence with the upper and lower lips falling back by an average of 3.3 mm ($p=0.004$) and 2.2 mm ($p=0.021$) respectively.

From T_0 to T_1 the most significant change occurring with treatment in the non-extraction group was confined to an increase in the lower incisor inclination (mean increase in IMPA of 5.7° , $p=0.046$) (Annexure 1C), hence resulting in a more acute interincisal angle (mean increase of 7.3° , $p=0.026$) and mild lower lip procumbency (mean 1.6 mm, $p=0.009$) at the end of active treatment (Table I).

At the end of active treatment, the only significant changes observed between the premolar extraction and non-extractions groups were a more acute interincisal angle ($p=0.004$) and greater lower lip vermilion thickness in the non-extraction group ($p=0.023$) as seen in Table II.

Assessing the net differences amongst the two groups at the end of treatment, as seen in Table II, the non-extraction group showed changes in incisor inclination (more acute interincisal angle at T_1 , $p=0.005$), with a mild increase in lower lip thickness ($p=0.011$) and

procumbency (p=0.001). The premolar extraction group showed greater changes in incisor position (retraction into extraction site) resulting in greater soft tissue changes with significant reduction in the procumbency of the upper (p=0.004) and lower lips (p=0.001).

Pearson's coefficients of correlation (r) were calculated to assess the degree of correlation amongst different variables (Table III). Significant correlations were noted amongst the hard (dental) and soft tissue variables, with the upper and lower lips correlating not only with each

Table I: Pre-treatment to post-treatment changes in the extraction and non-extraction groups.

	Extraction (n=17)				p-value	Non-extraction (n=17)				p-value
	Pre-Tx		Post-Tx			Pre-Tx		Post-Tx		
	Mean	SD	Mean	SD		Mean	SD	Mean	SD	
SNA	82.29	5.46	82.24	5.25	.000 ***	82.47	3.24	81.24	2.46	.069
SNB	79.29	6.01	78.94	5.11	.548	79.59	3.74	78.41	2.67	.143
ANB	5.00	2.97	3.29	2.73	.005 **	3.47	1.41	2.82	1.46	.094
SN-MP	33.76	6.76	34.00	7.16	.410	32.82	5.58	33.18	5.74	.422
I.I.A	117.88	10.16	122.59	5.69	.099	121.76	10.85	114.47	8.83	.026 *
UI-SN	112.47	8.78	107.71	7.03	.093	110.29	8.43	111.00	5.38	.700
IMPA	97.18	6.96	96.24	6.63	.611	96.29	9.35	102.00	10.45	.046 *
UI-SP	77.65	8.73	72.53	8.43	.000 ***	73.94	4.60	73.71	4.97	.739
LI-SP	73.29	9.64	70.41	8.65	.001 ***	69.00	4.63	70.71	4.62	.026 *
Ss-E line	-8.24	4.64	-9.65	5.19	.005 **	-10.06	2.75	-11.18	2.22	.040 *
Ls- E line	-2.00	2.42	-4.29	2.88	.009 **	-3.94	3.83	-2.41	4.91	.270
Li- E line	1.00	2.47	-1.35	1.90	.000 ***	-1.47	3.15	-0.41	2.83	.024 *
Si- E line	-5.59	2.42	-6.53	2.37	.016 *	-7.00	2.43	-6.71	2.42	.311
UL-SP	88.65	8.86	85.35	8.75	.004 **	86.24	4.86	86.47	4.41	.672
LL-SP	84.82	10.43	82.59	9.91	.021 *	82.24	4.71	83.82	5.34	.009 **
NLA	101.65	27.95	112.12	8.86	.135	105.29	12.06	107.12	9.85	.439
MLA	118.24	17.52	122.41	15.42	.274	114.18	14.08	111.82	15.01	.508
ULT	11.82	2.07	12.65	2.62	.150	12.41	2.09	13.65	2.03	.053
LLT	17.41	2.50	15.71	2.52	.081	16.47	1.51	17.65	1.69	.125
St - St	2.76	3.51	0.06	0.24	.005 **	1.35	2.69	0.65	1.49	.376

N=34; Paired sample t-test; * p-value ≤ .05; ** p-value ≤ .01; *** p-value ≤ .001.

Key for abbreviations: IIA = Interincisal angle; St-St = Stomion to stomion; UI-SP = Upper incisor to sella-perpendicular; LI-SP = Lower incisor to sella-perpendicular; Ss-E line = Sulcus superior to E-line; Ls-E line = Labrale superior to E-line; Li-E line = Labrale inferior to E-line; Si-E line = Sulcus inferior to E-line; UL-SP = Upper lip to sella-perpendicular; LL-SP = Lower lip to sella-perpendicular; NLA = Nasolabial angle; MLA = Mentolabial angle; ULT = Upper lip thickness; LLT = Lower lip thickness.

Table II: Post-treatment appraisal of extraction and non-extraction groups and the net differences amongst the two groups at end the of treatment.

	Post-treatment values					Net difference after treatment				
	Extraction		Non-extraction		p-value	Extraction		Non-extraction		p-value
	Mean	SD	Mean	SD		Mean	SD	Mean	SD	
SNA	82.24	5.25	81.24	2.46	.484	2.06	1.52	1.24	2.61	.271
SNB	78.94	5.11	78.41	2.67	.709	0.35	2.37	1.18	3.15	.396
ANB	3.29	2.73	2.82	1.46	.537	1.70	2.14	0.65	1.49	.106
SN-MP	34.00	7.16	33.18	5.74	.714	-0.24	1.15	-0.35	1.76	.820
I.I.A	122.59	5.69	114.47	8.83	.004 *	-4.71	11.08	7.29	12.29	.005 **
UI-SN	107.71	7.02	111.00	5.38	.135	4.76	11.00	-0.71	7.41	.100
IMPA	96.24	6.62	102.00	10.45	.065	0.94	7.87	-0.51	10.50	.042 *
UI-SP	72.53	8.43	73.71	4.97	.624	5.11	4.35	0.23	2.86	.001 **
LI-SP	70.41	8.65	70.71	4.62	.903	2.88	2.97	-1.70	2.86	.000 ***
Ss-E line	-9.65	5.19	-11.18	2.21	.276	1.41	1.76	1.12	2.05	.658
Ls- E line	-4.29	2.88	-2.41	4.99	.185	2.29	3.17	-1.52	5.52	.020 *
Li- E line	-1.35	1.09	-0.41	2.83	.265	2.35	1.27	-1.05	1.75	.000 ***
Si- E line	-6.53	2.38	-6.71	2.42	.831	0.94	1.13	-0.29	1.15	.010 **
UL-SP	85.35	8.78	86.47	4.42	.644	3.29	4.05	-0.23	2.25	.004 **
LL-SP	82.59	9.92	83.82	5.34	.655	2.23	3.59	-1.58	2.20	.001 ***
NLA	112.12	8.86	107.12	9.85	.130	-10.47	27.43	-1.82	9.47	.234
MLA	122.41	15.42	111.82	15.01	.051	-4.17	15.18	2.35	14.32	.207
ULT	12.65	2.62	13.65	2.06	.184	-0.82	2.24	-1.23	2.32	.612
LLT	15.71	2.52	17.76	2.51	.023 *	1.58	2.34	-0.82	2.85	.011 **
St - St	0.06	0.24	0.65	1.50	.128	2.70	3.44	0.70	3.19	.089

N=34; Independent sample t-test; * p-value ≤ .05; ** p-value ≤ .01; *** p-value ≤ .001.

Key for abbreviations: IIA = Interincisal angle; St-St = Stomion to stomion; UI-SP = Upper incisor to sella-perpendicular; LI-SP = Lower incisor to sella-perpendicular; Ss-E line = Sulcus superior to E-line; Ls-E line = Labrale superior to E-line; Li-E line = Labrale inferior to E-line; Si-E line = Sulcus inferior to E-line; UL-SP = Upper lip to sella-perpendicular; LL-SP = Lower lip to sella-perpendicular; NLA = Nasolabial angle; MLA = Mentolabial angle; ULT = Upper lip thickness; LLT = Lower lip thickness.

Table III: Correlation amongst hard (dental) and soft tissue parameters.

	I.I.A	Ss – E	UI-SN	IMPA	Ls – E	Li – E	Si – E	NLA	MLA	UL – SP	UI – SP	LL – SP	LI – SP	UL THK	LL THK
I.I.A	1	.121	-.683**	-.716**	-.212	-.413*	-.023	.238	.101	-.312	-.598**	-.280	-.584**	.109	-.248
Ss – E		1	-.095	-.153	.230	.398*	.359*	.448**	-.197	-.276	-.371*	-.231	-.485**	-.053	.300
UI-SN			1	.109	.066	.202	-.183	-.543**	-.101	-.538**	.722**	.371*	.411*	.104	.241
IMPA				1	.200	.262	.067	.100	-.116	-.055	-.168	.051	.481**	-.249	.023
Ls – E					1	.452**	.546**	-.126	.060	.163	.103	.076	.095	.158	.064
Li – E						1	.609**	.026	-.209	.280	.277	.386*	.239	.232	.675**
Si – E							1	.285	.374*	-.091	-.136	.099	-.049	-.034	.095
NLA								1	.085	-.588**	-.643**	-.368*	-.398*	-.317	-.153
MLA									1	-.200	-.130	-.090	-.084	-.194	-.611**
UL– SP										1	.721**	.757**	.588**	.544**	.288
UI – SP											1	.687**	.753**	.076	.304
LL – SP												1	.738**	.365*	.353*
LI – SP													1	.041	.090
UL THK														1	.305
LL THK															1

N= 34; Pearson's Correlation (r); * Correlation is significant at the 0.05 level; ** Correlation is significant at the 0.01 level.

Key for abbreviations: IIA = Interincisal angle; UI-SN = Upper incisor to SN plane angle; Ss-E line = Sulcus superior to E-line; Ls-E line = Labrale superior to E-line; Li-E line = Labrale inferior to E-line; Si-E line = Sulcus inferior to E-line; NLA = Nasolabial angle; MLA = Mentolabial angle; UL-SP = Upper lip to sella-perpendicular; LL-SP = Lower lip to sella-perpendicular; UI-SP = Upper incisor to sella-perpendicular; LI-SP = Lower incisor to sella-perpendicular; ULT = upper lip thickness; LLT = lower lip thickness.

other ($r=0.757$), but also with changes occurring in both upper and lower incisor positions. The nasolabial angle seemed to be significantly affected by upper incisor ($r=0.643$) and lip changes ($r=0.588$).

DISCUSSION

Attaining (or maintaining) general harmony and balance among the various facial features by predicting the individual response to treatment becomes part of an orthodontist's responsibility.

Comparison of the two study groups at the start of treatment reveals that although there were no significant morphological differences, the extraction group displayed greater mandibular crowding and a more protrusive lower lip relative to Rickett's E-line. Erdinc *et al.* discerned a similar lower lip pattern in their study sample;¹² however, as did Bravo *et al.*¹³ they also found a number of differences at the dental level, including a significantly reduced interincisal angle.

Several studies have attempted to determine the effects of extraction versus non-extraction treatment on the soft tissue profile, owing to the opposite mechanics undertaken in both treatment approaches.¹²⁻¹⁶ Kokadereli concluded that the main soft tissue differences between the groups were retruded upper and lower lips in the extraction sample.¹⁴ Similarly in this study, the extraction group showed significant retraction of the upper and lower lips in response to incisor retraction, which was also responsible for a significant reduction in the SNA angle (mean 2°) due to retraction of point A. The non-extraction group finished with a mild increase in the procumbency of the lower lip in response to increases in IMPA and interincisal angle, pointing towards the displacement of mandibular incisors in a direction opposite to that seen in extraction cases, with the intention

of gaining space in the arch. These observations agree with those reported by Erdinc *et al.* and Bravo *et al.*^{12,13}

Post-treatment comparison of the net differences taking place with treatment between both groups with reference to each other showed that significant changes in the soft tissue profile were mostly confined to the group treated with premolar extractions. Various researchers using different reference planes have also observed similar changes in extraction patients,^{12,13,17,18} notably reduction in angle SNA as well as in lip procumbency, resulting in improvement of the profile.

Although extraction mechanotherapy has often been associated with flattening of the facial profile, the results achieved in this study showed no significant difference in lip position of premolar extraction patients when compared with those cases treated without extractions, signifying that both treatment modalities finished within the same soft tissue parameters. Similar observations have been reported by different authors including Young and Smith, who suggest that extractions have no unfavourable effect on the facial profile if the decision to extract is based on sound diagnostic criteria.^{16,19-21} Ismail and Moss examined the three-dimensional effects of extraction and non-extraction orthodontic treatment on the facial soft tissues using optical scans and concluded that the effects of the two types of treatment on the facial soft tissues were very similar,⁶ indicating that orthodontic treatment involving the extraction of teeth does not have a detrimental effect on the face.

Tadic and Woods agreed, further elaborating that the degree to which changes in lip positions may be affected by anteroposterior tooth movements depend on the treatment mechanics used, the various extraction decisions, the final angulations of the upper and lower incisors, the pretreatment lip thickness, and the underlying vertical and anteroposterior facial patterns.²²

Annexure 1

Although numerous studies have concentrated on the hard-to-soft tissue relationship, the nature of correlation between the two, still seems indeterminate. Comparison between the two shows that; the upper lip is more variable in its response than the lower lip to differences in incisor retraction,^{10,23,24} with the lower lip showing high correlations with upper and lower incisor retraction. Research concludes changes in lower lip in response to orthodontic tooth movement as more predictable than those of the upper lip, as the complex functional musculoskeletal anatomy of the nasomaxillary complex contributes to the variability of upper lip response to extraction therapy.^{10,22,23} Caplan and Shivapuja's findings with regards to soft tissue correlation, support the present¹⁰ where the high correlation between the upper and lower lips suggests that the soft tissue structures of the lips tend to support each other.

Although prediction of soft tissue response to orthodontic tooth movement is complex, and would require the application of further tests (multiple regression), the significant changes occurring with orthodontic treatment verify the fact that such relationships in fact do exist, and advanced research could lead to greater understanding and even better treatment results.

CONCLUSION

The premolar extraction group showed a significant reduction in lip procumbency while the non-extraction group showed mild increase in IMPA and lower lip procumbency at the end of active treatment. Extraction and non-extraction groups finished within the same soft tissue parameters, signifying that premolar extraction does not necessarily cause undesirable changes in the soft tissue profile. Significant correlations existed between the hard (dental) and soft tissue variables, indicating that advanced studies could predict the nature of response of the soft tissue profile to orthodontic tooth movement.

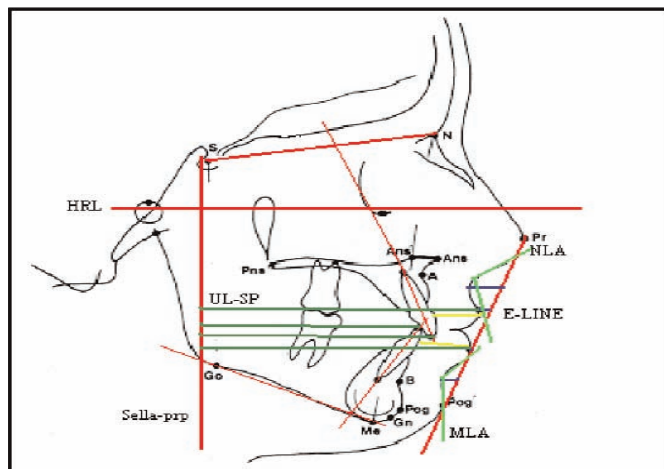


Figure 1: Cephalometric measurements used to evaluate soft tissue profile.

1A. Cephalometric points:

Nasion (N): Most anterior point of frontonasal suture in median plane.

Sella (S): Mid-point of concavity of sella turcica.

Pronasale (Pr): Most prominent point on the tip of the nose.

Subnasale (Sn): Point at junction of columella and upper lip

Sulcus superior (Ss): Point of greatest concavity between Ls and Sn.

Labrale superior (Ls): Most anterior point on convexity of upper lip.

Labrale inferior (Li): Most anterior point on convexity of lower lip.

Sulcus inferior (Si): Point of greatest concavity between Li and Pog'.

Soft-tissue pogonion (Pog'): Most anterior point on soft-tissue chin.

Point A (A): Point at deepest midline concavity on maxilla between anterior nasal spine and prosthion.

Point B (B): Point at deepest midline concavity on mandibular symphysis between infradentale and pogonion.

1B. Cephalometric lines:

Horizontal reference line (HRL): Horizontal line constructed 7° inferior to sella-nasion plane at the level of the Frankfort horizontal plane.

Sella-perpendicular (SP): Perpendicular dropped through S from the HRL.

E-line: Ricketts' Esthetic line extending between Pr and Pog'.

Ss to E-line: Linear distance from sulcus superior to the E-line.

Ls to E-line: Linear distance from labrale superior to the E-line.

Li to E-line: Linear distance from labrale inferior to the E-line.

Si to E-line: Linear distance from sulcus inferior to the E-line.

Upper lip vermilion thickness (UVT): Linear distance from most facial point of maxillary incisor to the vermilion border of upper lip.

Lower lip vermilion thickness (LVT): Linear distance from most facial point of mandibular incisor to Li.

Upper lip to SP (UL-SP): Linear distance from Ls to SP.

Lower lip to SP (LL-SP): Linear distance from Li to SP.

Upper incisor to SP (UI-SP): Linear distance from the most proclined maxillary incisal tip to SP.

Lower incisor to SP (LI-SP): Linear distance from the most proclined mandibular incisal tip to SP.

Stomion-stomion (St-St): Interlabial gap.

Axial inclination of maxillary incisor.

Axial inclination of mandibular incisor.

1C. Cephalometric angles:

SNA: Sella to nasion to A point angle.

SNB: Sella to nasion to B point angle.

ANB: Sagittal skeletal discrepancy angle, A to Na to B.

SN-MP: Mandibular plane (Me-Go) to SN plane angle.

UI-SN: Maxillary central incisor to SN plane angle.

IMPA: Mandibular incisor to mandibular plane angle.

Interincisal angle (IIA): Formed by intersection of maxillary and mandibular incisor axial inclinations.

Nasolabial angle (NLA): Formed by the intersection of a line originating at Sn, tangent to the lower border of the nose, and a line from Sn to Ls.

Mentolabial angle (MLA): Formed by intersection of line traced between Li and Si, and line traced between Si and Pog'.

REFERENCES

- Erbay EF, Caniklioglu CM. Soft tissue profile in Anatolian Turkish adults: Part II. Comparison of different soft tissue analyses in the evaluation of beauty. *Am J Orthod Dentofacial Orthop* 2002; **121**: 65-72.
- Proffit WR. Forty-year review of extraction frequencies at a university orthodontic clinic. *Angle Orthod* 1994; **64**:407-14. Comment in: p. 403.
- Ribarevski R, Vig P, Vig KD, Weyant R, O'Brien K. Consistency of orthodontic extraction decisions. *Eur J Orthod* 1996; **18**:77-80.
- Proffit WR. Contemporary orthodontics. 3rd ed. Missouri: Elsevier Inc 2000.
- Luppanapornlarp S, Johnston LE. The effects of premolar-extraction: a long-term comparison of outcomes in 'clear-cut' extraction and non-extraction Class II patients. *Angle Orthod* 1993; **63**:257-72.
- Ismail SF, Moss JP. The three-dimensional effects of orthodontic treatment on the facial tissues: a preliminary study. *Br Dent J* 2002; **192**:104-8.
- Bishara SE, Cummins DM, Zaher AR. Treatment and post-treatment changes in patients with Class II Division 1 malocclusion after extraction and non-extraction treatment. *Am J Orthod Dentofacial Orthop* 1997; **111**:18-27.
- Wholley CJ, Woods MG. The effects of commonly prescribed premolar extraction sequences on the curvature of the upper and lower lips. *Angle Orthod* 2003; **73**:386-95.
- Kumari M, Fida M. Vertical facial and dental arch dimensional changes in extraction versus non-extraction orthodontic treatment. *J Coll Physicians Surg Pak* 2010; **20**:17-21.
- Caplan MJ, Shivapuja PK. The effect of premolar extractions on the soft tissue profile of adult African American females. *Angle Orthod* 1997; **67**:129-36. Erratum in: *Angle Orthod* 1997; **67**(3):240.
- Lai J, Ghosh J, Nanda R. Effects of orthodontic therapy on the facial profile in long and short vertical facial patterns. *Am J Orthod Dentofacial Orthop* 2000; **118**:505-13.
- Erdinc AE, Nanda RS, Dandajena TC. Profile changes of patients treated with and without premolar extractions. *Am J Orthod Dentofacial Orthop* 2007; **132**:324-31.
- Bravo LA, Canut JA, Pascual A, Bravo B. Comparison of the changes in facial profile after orthodontic treatment, with and without extractions. *Br J Orthod* 1997; **24**:25-34.
- Kocadereli I. Changes in soft tissue profile after orthodontic treatment with and without extractions. *Am J Orthod Dentofacial Orthop* 2002; **122**:67-72.
- Stephens CK, Boley JC, Behrents RG, Alexander RG, Buschange PH. Long-term profile changes in extraction and non-extraction patients. *Am J Orthod Dentofacial Orthop* 2005; **128**:450-7.
- Young TM, Smith RJ. Effects of orthodontics on the facial profile: a comparison of changes during non-extraction and four premolar extraction treatment. *Am J Orthod Dentofacial Orthop* 1993; **103**:452-8.
- Bravo LA. Soft tissue facial profile changes after orthodontic treatment with four premolars extracted. *Angle Orthod* 1994; **64**: 31-42.
- Scott Conley R, Jernigan C. Soft tissue changes after upper premolar extraction in Class II camouflage therapy. *Angle Orthod* 2006; **76**:59-65.
- Bowman SJ, Johnston LE Jr. The esthetic impact of extraction and non-extraction treatments on Caucasian patients. *Angle Orthod* 2000; **70**:3-10.
- Xu TM, Liu Y, Yang MZ, Huang W. Comparison of extraction versus non-extraction orthodontic treatment outcomes for borderline Chinese patients. *Am J Orthod Dentofacial Orthop* 2006; **129**:672-7.
- Basciftci FA, Usumez S. Effects of extraction and non-extraction treatment on Class I and II subjects. *Angle Orthod* 2003; **73**:36-42.
- Tadic N, Woods MG. Incisal and soft tissue effects of maxillary premolar extraction in Class II treatment. *Angle Orthod* 2007; **77**:808-16.
- Talass MF, Talass L, Baker RC. Soft tissue profile changes resulting from retraction of maxillary incisors. *Am J Orthod Dentofacial Orthop* 1987; **91**:385-94.
- Kasai K. Soft tissue adaptability to hard tissues in facial profiles. *Am J Orthod Dentofacial Orthop* 1998; **113**:674-84.

.....★.....