



THE AGA KHAN UNIVERSITY

eCommons@AKU

---

Section of Orthopaedic Surgery

Department of Surgery

---

2011

## Osteochondral grafting of knee joint using mosaicplasty

Muhammad Abdul Wajid

*Aga Khan University*, [muhammad.wajid@aku.edu](mailto:muhammad.wajid@aku.edu)

Muhammad Idrees Shah

*Aga Khan University*

Mohsin e. Azam

*Aga Khan University*

Tashfeen Ahmad

*Aga Khan University*

Follow this and additional works at: [https://ecommons.aku.edu/pakistan\\_fhs\\_mc\\_surg\\_orthop](https://ecommons.aku.edu/pakistan_fhs_mc_surg_orthop)



Part of the [Orthopedics Commons](#), and the [Surgery Commons](#)

---

### Recommended Citation

Wajid, M. A., Shah, M. I., Azam, M. e., Ahmad, T. (2011). Osteochondral grafting of knee joint using mosaicplasty. *Journal of the College of Physicians and Surgeons Pakistan*, 21(3), 184-186.

Available at: [https://ecommons.aku.edu/pakistan\\_fhs\\_mc\\_surg\\_orthop/22](https://ecommons.aku.edu/pakistan_fhs_mc_surg_orthop/22)

# Osteochondral Grafting of Knee Joint Using Mosaicplasty

Muhammad Abdul Wajid, Muhammad Idrees Shah, Mohsin-e-Azam and Tashfeen Ahmad

## ABSTRACT

Focal cartilage defects of articular surface-traumatic and degenerative are difficult to treat, thus a variety of surgical techniques have been developed and reported for treatment of such defects. Procedures such as Priddies perforations, microfracture, abrasion chondroplasty have shown long-term results which are often less than adequate. One of the reasons is that all these techniques lead to the formation of fibrocartilage which has inferior mechanical properties as compared to the native hyaline cartilage. Mosaicplasty is a procedure which aims at replacing the lost articular cartilage with hyaline cartilage including underlying bone support, thus providing adequate stability to the cartilage and better cartilage/bone integration. A young man underwent this procedure for recalcitrant knee pain at our institution. At 2 years follow-up, his knee pain has significantly improved. We hereby present medium term results (2 years) of this first case report in local literature.

**Key words:** *Osteochondritis dissecans. Osteochondral defect. Osteochondral grafting. Mosaicplasty. Knee joint.*

## INTRODUCTION

Osteochondral defects in joints are a challenging problem to deal with. These are localized defects of the articular cartilage in an otherwise normal joint, and usually occur in young, active individuals often involved in sports. Due to poor repair potential of articular hyaline cartilage, the natural history of un-treated defects is that, at worst the defects get filled with fibrocartilage and at best remain as such. In the latter case, the joint surface remains irregular, producing reciprocal damage to the opposing cartilage surface with motion of the joint, and degenerative arthritis eventually ensues. In a long-term follow-up of a small group of young patients noted to have chondral defects at arthroscopy, there was a high rate of radiological evidence of osteoarthritis although most patients had few symptoms.<sup>1</sup> Thus, surgical intervention to address the defect has been advocated for these patients.

Different surgical methods have been employed for the management of osteochondral defects, including debridement,<sup>2</sup> microfracture,<sup>3</sup> mosaicplasty,<sup>3</sup> perichondrial grafts,<sup>4</sup> carbon fiber insertion, osteotomy, periosteal grafts,<sup>5</sup> and autologous chondrocyte implantation,<sup>6</sup> giving variable results.

Mosaicplasty (Mosaic grafting) is one of the techniques used in management of osteochondral defects. It entails harvesting osteochondral grafts from non-articular regions of the joint and placing it in the defect. The

technique was developed and perfected by Hangody in Hungary in early 1990s, with animal experiments conducted in 1991 and first human grafts carried out in 1992.

There is a one-stage procedure where multiple osteochondral plugs are harvested with a cylindrical cutting device from a non-articulating region of joint surface and are used to fill an articular cartilage defect. In the knee commonly used donor sites are non-weight-bearing patellofemoral area and edges of medial and lateral femoral condyles. Instead of using one osteochondral autograft block, multiple small osteochondral cylinders are placed next to each other covering the articular defect and thus maintaining the radius of curvature of the articular surface. Cylindrical holes of appropriate depth and diameter are made and the graft is inserted. The technique is usually undertaken as an open procedure, although it is possible to perform it arthroscopically. Advantages of this technique are that the defects can be filled immediately with mature hyaline articular cartilage, and that both chondral and osteochondral defects can be treated with the same method.

Although this technique is regularly used in the West, no report on the use of this technique has been published from Pakistan. The objective of this first case report is to present the medium term (24-month) outcome of osteochondral grafting of the knee joint by open technique.

## CASE REPORT

A 45 years old male who presented with a 6-months history of increasing pain in the left knee and difficulty in squatting. Knee examination revealed that he had normal alignment, no effusion and range of movement from 0-130 degrees. However, terminal movements were painful. No significant joint line tenderness was present. X-rays showed no significant bony changes. He

*Section of Orthopaedics, Department of Surgery, The Aga Khan University Hospital, Karachi.*

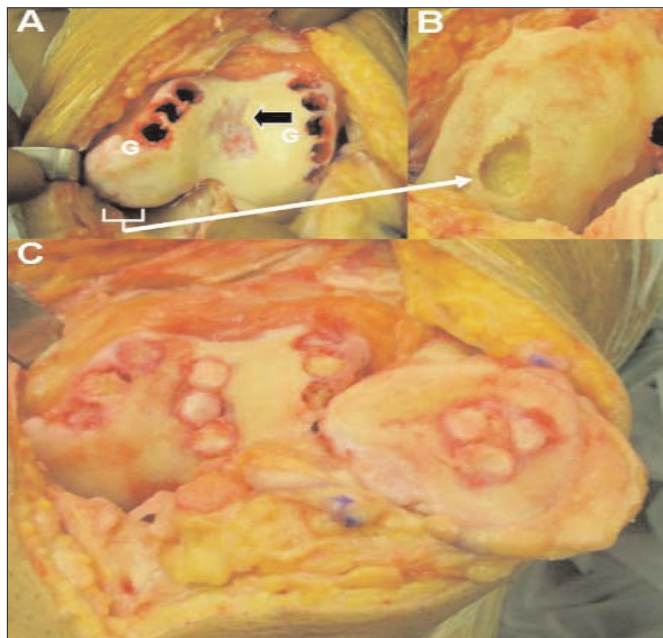
**Correspondence:** *Dr. Muhammad Abdul Wajid, Section of Orthopaedics, Department of Surgery, The Aga Khan University Hospital, Stadium Road, Karachi.*

*E-mail: muhammad.wajid@aku.edu*

*Received January 25, 2010; accepted January 12, 2011.*

was initially treated non-operatively with oral analgesics and physiotherapy, but his symptoms failed to subside, hence an arthroscopy of the knee was performed. Arthroscopy revealed a chondral defect measuring 1x1 cm over the medial femoral condyle in the weight-bearing region, and a tear in the posterior horn of the medial meniscus. Partial meniscectomy was done at that time and no intervention was done to the chondral defect. Postoperatively his symptoms improved initially but he was not able to squat due to pain.

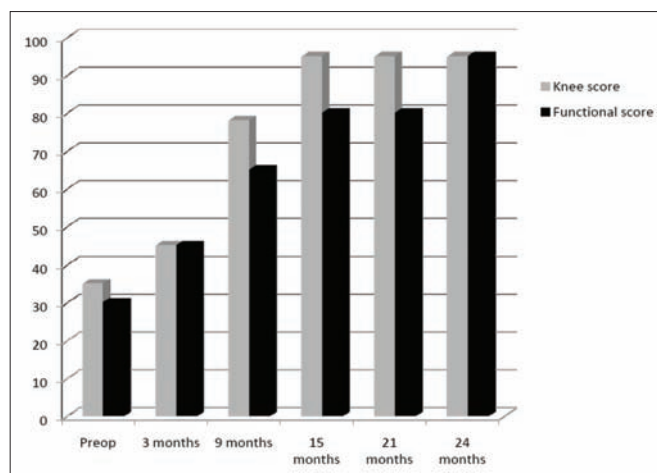
As his symptoms were not resolving he was offered osteochondral grafting, to which he agreed. First an arthroscopic examination was done which showed that the femoral condyle defect had progressed from 1x1 cm to 2x1 cm, and he also had developed a 2x1 cm defect of femoral trochlea (Figure 1A black arrow) which probably was contributing to severe pain on squatting. Through an open approach, the recipient area was prepared with high speed burr and cartilage was removed to achieve right angle at the edges. In the base of the defect multiple small 6 mm diameter and about 10 mm deep vertical tunnels were made with bone trephines. Osteochondral graft was harvested from the non-articular part of distal femur using bone trephine of 5 mm diameter; nine cylindrical grafts of 15 mm length and 5 mm diameter were harvested (Figure 1A 'G'). Graft was then carefully tamped in the corresponding tunnels in the posteromedial femoral condyle, the femoral trochlea and the patella and length was adjusted after measuring the exact depth of the tunnel. The bone removed from recipient area was inserted in the donor area to fill the voids (Figure 1).



**Figure 1 (A-C):** Intra operative photograph of the left knee joint showing (A) defect in the femoral trochlea (black arrow), graft donor tunnels (G), defect in the posterior surface of medial femoral condyle (white arrow, A and B). Final appearance (C) of distal femur and patella following completion of osteochondral grafting. The grafted defects in the femoral trochlea and patella are visible.

Postoperatively he was allowed range of motion exercises but kept non-weight-bearing for 6 weeks. Weight bearing was then allowed as tolerated but squatting was not allowed for 2 months. His pain started to improve after 6 weeks.

Follow-up assessment was done at regular intervals and knee function was assessed using Knee Society Score. He achieved good outcome as assessed clinically and also by improvement of the knee society score at 9 months. This was maintained till his last follow-up at 24 months at which he showed substantial improvement in symptoms, full range of motion in the knee joint and improved quality of life. His pre- and postoperative Knee Society Score is shown in Figure 2.



**Figure 2:** Graph showing change in knee society score of the patient over the follow-up period. Progressive improvement in both components of the score is apparent.

In order to evaluate the quality of graft stability and bone integration, MRI scan was done at 16 months post-operative which showed good graft incorporation and restoration of articular surface. The cartilage returned normal signal, similar to the native hyaline cartilage adjacent to the defect.

## DISCUSSION

Defects in the articular cartilage of knee joint may result either from acute high energy trauma or repetitive shear and torsional forces to the superficial zone of articular cartilage.

Knee cartilage defects are commonly found by magnetic resonance imaging (MR imaging) in healthy subjects and by arthroscopy in symptomatic subjects, in whom they are thought to be largely traumatic. Osteochondral defects are thought to cause osteoarthritis in affected joint in animal studies.<sup>7</sup> The incidence of cartilage defect on arthroscopic examination of knee joint is approximately 5%.<sup>8</sup>

Articular cartilage is an avascular, aneural tissue that has limited repair capabilities compared with other mesenchymal tissues. Chondrocytes also have limited

migratory ability and, as a result, the surrounding normal cartilage cells do not fill the defect. Chondrocytes have a transient but insufficient response to injury. They increase their mitotic activity as well as their production of glycosaminoglycan and collagen but only for a short period of time and to a limited degree. Normal articular cartilage has only a few cells, which exist in isolated cell lacunae within the extra-cellular matrix, further decreasing the healing potential of articular cartilage.

These factors in combination with the continued use of the extremity by the individual, producing repetitive compressive and shear forces, create an extremely poor environment for spontaneous repair.<sup>9</sup> Only symptomatic, cartilage defects should be treated as there is no evidence to suggest that patients with asymptomatic lesions will become symptomatic in the future. Osteochondral defects in adults may warrant more aggressive attention because of the high incidence of early-onset osteoarthritis.<sup>10</sup>

Various surgical techniques have been described for the treatment of such defects, including abrasion chondroplasty, carbon fiber insertion and periosteal grafting. These techniques result in fibrocartilage scar tissue formation in the defect. Fibrocartilage is mechanically inferior to hyaline cartilage with different surface characteristics, hence does not arrest the sequelae of the initial defect, i.e. degenerative arthritis.

Alternative methods have been developed in an attempt to achieve filling of the defect with hyaline cartilage. These include osteochondral allografts or autografts, autologous periosteal grafting and autologous chondrocyte implantation. Autologous chondrocyte implantation entails an initial procedure for harvesting of hyaline cartilage from the patient, processing of the cartilage fragment to isolate chondrocytes, culturing them in a clinical-grade cell-culture facility, and subsequent implantation in the osteochondral defect in a second procedure, which may be arthroscopic or open surgery.<sup>11</sup> Many reports suggest that this method results in hyaline cartilage formation in the defect. However, success with this method has been variable, partly owing to the fact that chondrocytes may not retain their chondrocytic phenotype in culture, may de-differentiate into fibroblasts, and thus produce fibrocartilage instead of hyaline cartilage when re-implanted.

Autologous periosteal grafting involves resection of periosteum with the undersurface facing toward the defect, after the defect has been dechondrified. The crater is filled with organic cement and covered with the periosteal graft. Although the results are encouraging, this procedure is of limited use in large defects because large periosteal grafts are associated with donor site morbidity, and problems with articular congruence leading to biomechanical complications.

Osteochondral grafting is one of the treatment options used in the management of articular cartilage defects in the knee joint. Commonly known as "mosaicplasty", and entails harvesting small osteochondral cylindrical autografts from the non-articulating parts of the joint, and impacting them in a mosaic fashion into the defect such that the superficial cartilage surface of the grafts is flush with the adjacent normal cartilage, and the cancellous portion the grafts are deep within the subchondral bone. Eventual healing of the graft occurs by integration at the periphery with surrounding hyaline cartilage and bone.

It would be reasonable to suggest that only symptomatic chondral defects should be treated as there is no evidence to suggest that patients with asymptomatic lesions will become symptomatic in the future.<sup>10</sup>

## REFERENCES

1. Messner K, Maletius W. The long-term prognosis for severe damage to weight-bearing cartilage in the knee: a 14-year clinical and radiographic follow-up in 28 young athletes. *Acta Orthop Scand* 1996; **67**:165-8.
2. Hubbard MJ. Articular debridement versus washout for degeneration of the medial femoral condyle. A 5-year study. *J Bone Joint Surg Br* 1996; **78**:217-9. Comment in: *J Bone Joint Surg Br* 1996; **78**(5):854.
3. Steadman JR, Rodkey WG, Rodrigo JJ. Microfracture: surgical technique and rehabilitation to treat chondral defects. *Clin Orthop Relat Res* 2001:S362-9.
4. Bouwmeester SJ, Beckers JM, Kuijer R, van der Linden AJ, Bulstra SK. Long-term results of rib perichondrial grafts for repair of cartilage defects in the human knee. *Int Orthop* 1997; **21**:313-7.
5. Alfredson H, Lorentzon R. Superior results with continuous passive motion compared to active motion after periosteal transplantation. A retrospective study of human patella cartilage defect treatment. *Knee Surg Sports Traumatol Arthrosc* 1999; **7**:232-8.
6. Peterson L, Minas T, Brittberg M, Lindahl A. Treatment of osteochondritis dissecans of the knee with autologous chondrocyte transplantation: results at two to ten years. *J Bone Joint Surg Am* 2003; **85**-A:17-24.
7. Lefkoe TP, Trafton PG, Ehrlich MG, Walsh WR, Dennehy DT, Barrach HJ, et al. An experimental model of femoral condylar defect leading to osteoarthritis. *J Orthop Trauma* 1993; **7**:458-67.
8. Hjelle K, Solheim E, Strand T, Muri R, Brittberg M. Articular cartilage defects in 1,000 knee arthroscopies. *Arthroscopy* 2002; **18**:730-4.
9. Jones DG, Peterson L. Autologous chondrocyte implantation. *J Bone Joint Surg* 2006; **88**-A:2502-20.
10. Smith GD, Knutsen G, Richardson JB. A clinical review of cartilage repair techniques. *J Bone Joint Surg Br* 2005; **87**:445-9.
11. Ahmad T, Umer M, Lubbad L, Lakdawala RH, Siddiqui AA. First successful autologous chondrocyte implantation in Pakistan. *J Coll Physicians Surg Pak* 2008; **18**:185-7.

.....★.....